

# Whale's Tail Technique – A Novel Approach for Regeneration in Aesthetic Zone

Medha Sharma <sup>a</sup>, B. S. Avinash <sup>a\*</sup> and Rashmi Durga Kalyanam <sup>a</sup>

<sup>a</sup> Department of Periodontology, JSS Dental College and Hospital, Mysuru, India.

## Authors' contributions

This work was carried out in collaboration among all authors. Surgery was done by author MS under guidance of author BSA, author RK prepared manuscript. All authors read and approved the final manuscript.

## Article Information

### Open Peer Review History:

This journal follows the Advanced Open Peer Review policy. Identity of the Reviewers, Editor(s) and additional Reviewers, peer review comments, different versions of the manuscript, comments of the editors, etc are available here: <https://www.sdiarticle5.com/review-history/87720>

Received 12 March 2022

Accepted 24 May 2022

Published 27 May 2022

## Case Report

## ABSTRACT

The goal of present case report is to illustrate the success of a novel modified Whale's tail technique for regeneration in aesthetic zone. A 49 years old male patient reported to the department of Periodontology having chief complaints as pain and increasing space between his upper front tooth region. Clinical examination revealed midline diastema and 8mm pocket depth with grade-I mobility for left maxillary central incisor. Radiograph revealed presence of vertical bone loss. After phase-I therapy and frenectomy, modified Whale's tail technique was employed to achieve regeneration. 9 months postoperative results showed reduction in pocket depth and improvement in bone level.

*Keywords: Labial frenum; periodontal pocket; bone regeneration; aesthetics.*

## 1. INTRODUCTION

The key facet of the periodontal therapy is to eliminate the pockets. In the maxillary anterior region apart from pocket elimination, restoring esthetics remains as a challenge. So, usually in esthetic zone non-surgical approach is preferred as first line of treatment. But in certain cases of

extensive bone loss or persisting pocket depth, surgical therapy is considered. For achieving favorable results after periodontal regenerative procedures, primary closure of the osseous defect is crucial, or it may jeopardize the gain in clinical attachment level. The flap must be designed in a manner that maximum amount of soft tissue is conserved to attain full coverage of

\*Corresponding author: Email: [dr.avianshbs@jssuni.edu.in](mailto:dr.avianshbs@jssuni.edu.in);

the biological material emplaced in the hard tissue defect [1]. Michaelides & Wilson [2] recommended the use of papilla preservation technique for anterior dentition to optimize postoperative esthetics by sustaining the height of papilla. In 2009, Bianchi and Basetti [3] narrated a new surgical procedure the "Whale's tail" technique for regeneration of wide infrabony defects in esthetic zone. And later Kuriakose et al suggested modification for this technique to achieve better flap approximation.

The aim of the present case report is to illustrate the success of a novel modified Whale's tail technique in achieving primary closure of the flap followed by regeneration of the defect in aesthetic zone complexed by high frenum.

## 2. CASE REPORT

A systemically healthy 49 years old male patient reported to the department of Periodontology having chief complaints as Pain and increasing space between his upper front tooth region. On examination midline diastema, high frenal attachment was noted. On probing, Maxillary left central incisor had 8mm of periodontal pocket with Grade-I mobility. Trauma from occlusion and tongue thrusting habits were not present. Intraoral periapical radiograph revealed bone defect on mesial side of the left maxillary central incisor. The patient was diagnosed as Chronic localised Periodontitis. Scaling and root planning were performed as a part of Phase – 1 therapy and patient was educated about oral hygiene maintenance.

Conventional frenectomy was performed initially to relieve high frenal attachment. Local anaesthesia was given. A haemostat was held in to the depth of the vestibule engaging frenum to be resected. Two incisions were made one above and the other under surface of the haemostat. Incisions were continued till the triangular tissue was resected and the haemostat was free. Fibrous attachments were removed by further deep dissection on the bone. A diamond shaped wound was formed whose edges are approximated and sutured by using 3-0 black silk with simple interrupted suture and then covered with periodontal pack. Sutures were removed after 1 week and evaluated for wound healing after 1 month and 3 months.

Since there was no reduction in pocket depth, when evaluated 3 months after Frenectomy, Periodontal flap surgery was planned. Anterior

superior alveolar and nasopalatine nerve blocks were given using 2% Lignocaine HCL with adrenaline (1:80,000) local anaesthesia. Two semilunar incisions were given on either sides of the frenum. Mesially these semilunar incisions should excise only the base of the frenal attachment, such that it can maintain the continuity of the flap. Distally it was extended on the buccal, interdental, and palatal sides of central incisors as intrasulcular incisions. This extension allows the detachment of a wide, thick papilla- preserving flap which was reflected towards the palatal aspect from the buccal side. Root planing and complete debridement were done using hand instruments exposing 8mm depth intraosseous defect. After saline irrigation, alloplastic bone graft material (Nano crystalline hydroxyapatite and collagen membrane) was placed in the intraosseous defect. The papilla preserving flap was replaced and sutured with vicryl without tension. COE-PAK was used as periodontal dressing material over surgical area. Postoperative instructions, analgesics and antibiotics were given. Patient was asked to come for follow up after 7 days and after 1 month to evaluate postoperative healing and plaque control. Pocket depth was reduced to 5mm when examined at the end of 9 months. Radiograph revealed increase in bone height. Patient was advised for closure of midline diastema and referred to the department of orthodontics.

## 3. DISCUSSION

Along with improving prognosis of the teeth, improving esthetics also remains as an objective for Periodontal surgical therapy for Maxillary anterior teeth. Minimally Invasive Surgical Techniques explained by Cortellini & Tonetti [4] to preserve interdental tissue have limited flap extension and elevation. These flap designs improved the wound stability but challenged the additional advantages when biomaterials are placed for regeneration. Apart from conventional, modified and simplified papilla preservation flap designs, "Whale's tail" design introduced by Bianchi and Basetti provided the benefit of reduction in the average area of flap dehiscence. The systematic placement of incisions away from the osseous defects and biomaterial margins remains unique [5].

In the classical Whale's tail technique, initially two full- thickness vertical incisions were given on the tooth adjacent to the defect extending from mucogingival junction to distal angle. And then a horizontal incision was given to join the

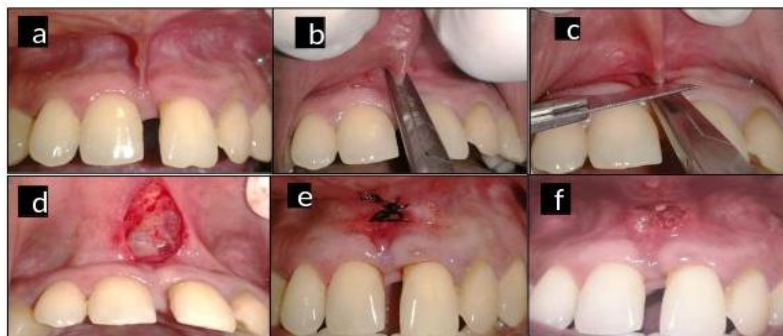
apical margins of the two vertical incision. Coronally this incisions were extended intra sulcularly on the buccal, interproximal and palatal sides of the defect- associated tooth. Later in the modified version of this technique two semilunar incisions on the buccal surface below the mucogingival junction were used alternate to conventional vertical and horizontal incisions, which aided in satisfactory flap closure and wound healing [6].

In the present case, this technique was chosen since the diastema is more than 2mm. High frenal attachment remains as a contraindication for Whale's tail technique, so frenectomy was done and flap surgery was planned 3 months after frenectomy for complete healing of frenum. Following the flap surgery, Clinical examination 9 months post operatively showed reduction of 3mm in periodontal pocket depth without mobility. These findings are similar to other studies Bianchi and Bassetti who reported reduction in the pocket depth of about  $5.8 \pm 2.5$  mm, and mean attachment level gain of  $4.9 \pm 1.8$  mm. Kuriakose *et al*, Damante *et al*. detailed a 4mm gain in the clinical attachment level [7].

This minimally invasive surgical technique has advantage of improved access to the defect, more convenient and ease of handling interdental papilla when compared to papilla preservation flap. Placement of incisions distant from the biomaterial, helps in preventing inflammatory response in the surgical area thereby reducing the chances for graft reduction [8]. The limitations of this can be it is highly technique sensitive and is not suggested for thin gingival biotype as it may cause recession [5]. Apart from the surgical procedure, patient compliance, environmental and behavioural aspects also influence the treatment outcome [9].

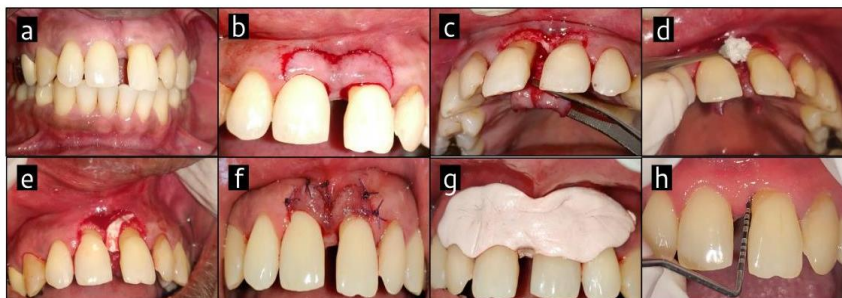
Rath *et al*. [10] used perio glass with GTR membrane and patil *et al*. [11] placed demineralized freeze-dried bone graft with amniotic membrane in the defect following whale's tail approach. These case reports showed positive results, suggesting this technique can be considered for regeneration in aesthetic zone. Systematic review also stated that whale's tail technique can be successfully used for esthetically pleasing results [12].

Figure 1



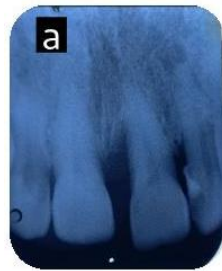1a.Preoperative showing aberrant frenal attachment. 1b. Frenum was engaged with hemostat. 1c.Incision given above hemostat. 1d. Diamond shaped wound. 1e.sutures were placed. 1f. 1-week post operative

Figure 2

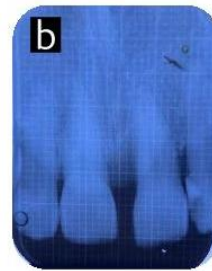


2a.Preoperative. 2b. semilunar incisions made on both sides of frenum. 2c. Defect visualization. 2d. Placement of bone graft. 2e.Placement of collagen membrane. 2f.sutures placed. 2g.periodontal dressing placed. 2h. 9 months Postoperative

Figure 3



3a. Pre operative radiograph



3b. 9 months post operative radiograph

#### 4. CONCLUSION

In modern dentistry, aesthetics has become the key objective when finalizing a treatment plan. So, in the maxillary incisor region with wide infrabony defects, "Modified whale's tail" flap design can be considered as clinical improvement of the soft and hard tissues is well documented, sustaining the interproximal tissues to restore a functional attachment with aesthetic results.

#### ETHICAL APPROVAL

As per international standard or university standard written ethical approval has been collected and preserved by the author(s).

#### CONSENT

Patient was informed and consent was taken regarding publication of this case with images.

#### DISCLAIMER

The products used for this research are commonly and predominantly use products in our area of research and country. There is absolutely no conflict of interest between the authors and producers of the products because we do not intend to use these products as an avenue for any litigation but for the advancement of knowledge. Also, the research was not funded by the producing company rather it was funded by personal efforts of the authors.

#### ACKNOWLEDGEMENT

We would like to thank JSS Dental college and hospital for providing all the facilities required.

#### COMPETING INTERESTS

Authors have declared that no competing interests exist.

#### REFERENCES

1. Mani A, Pendyala G, Lawande A, Patil A. The papilla preservation flap surgery: A Review. *Irijet*. 2018;1663-5.
2. Michaelides PL, Wilson SG. A comparison of papillary retention versus full-thickness flaps with internal mattress sutures in anterior periodontal surgery. *Int J Periodontics Restorative Dent*. 1996 Aug;16(4):388-97. PMID: 9242106.[pubmed]
3. Bianchi AE, Bassetti A. Flap design for guided tissue regeneration surgery in the esthetic zone: The "whale's tail" technique. *Int J Periodontics Restorative Dent*. 2009 Apr;29(2):153-9. PMID: 19408477. [pubmed]
4. Cortellini P, Tonetti MS. A minimally invasive surgical technique with an enamel matrix derivative in the regenerative treatment of intra-bony defects: a novel approach to limit morbidity. *J Clin Periodontol*. 2007 Jan;34(1):87-93. DOI: 10.1111/j.1600-051X.2006.01020.x. PMID: 17243998.[pubmed]
5. Mrunal DM, Jaypal JS, Wilson RS, Chatterjee A. Whale's tail technique: A case series. *J Indian Soc Periodontol*. 2016 Jul-Aug;20(4):460-463. DOI: 10.4103/0972-124X.188333. PMID: 28298831; PMCID: PMC5341324. [pubmed]
6. Kuriakose A, Ambooken M, Jacob J, John P. Modified Whale's tail technique for the

- management of bone-defect in anterior teeth. J Indian Soc Periodontol. 2015 Jan-Feb;19(1):103-6.  
DOI: 10.4103/0972-124X.145826. PMID: 25810604;  
PMCID: PMC4365146.[pubmed]
7. Damante CA, Sant'Ana AC, Rezende ML, Greggi SL, Passanezi E. Guided tissue regeneration and papilla preservation with whale's tail flap. JSM Dent. 2013;1:1017- 21
  8. Vijay DM, Deepika PC, Sharma HM. Whale's tail technique. J Int Clin Dent Res Organ. 2019;11:110-3.
  9. Tonetti MS, Prato GP, Cortellini P. Factors affecting the healing response of intrabony defects following guided tissue regeneration and access flap surgery, J. Clin. Periodontol. 1996;23:548–556.
  10. Rath A, Fernandes BA, Sidhu P, Hr P. Surgical management of wide intrabony defect underlying midline diastema using Whale's tail flap technique: A Case Report. Int J Surg Case Rep. 2018;49:166-169. DOI: 10.1016/j.ijscr.2018.07.006. Epub 2018 Jul 11. PMID: 30015214; PMCID: PMC6070683.
  11. Patil AG, Bhatt VH. Modified whale's tail technique using amnion membrane for periodontal regeneration in the anterior teeth with diastema: A case report. Indian Journal of Case Reports. 2019;5(5):457-460. Available:https://doi.org/10.32677/IJCR.2019.v05.i05.019
  12. Graziani F, Gennai S, Cei S, Cairo F, Baggiani A, Miccoli M, et al. Clinical performance of access flap surgery in the treatment of the intrabony defect. A systematic review and meta-analysis of randomized clinical trials. J Clin Periodontol. 2012;39:145-56.

© 2022 Sharma et al.; This is an Open Access article distributed under the terms of the Creative Commons Attribution License (<http://creativecommons.org/licenses/by/4.0>), which permits unrestricted use, distribution, and reproduction in any medium, provided the original work is properly cited.

*Peer-review history:*

*The peer review history for this paper can be accessed here:  
<https://www.sdiarticle5.com/review-history/87720>*