



## Aortic Remodeling and Human Immunodeficiency Virus Infection: Two Case Reports

Jospin Karel Makani Bassakouahou<sup>a,\*</sup>, Christian Michel Kouala Landa<sup>b</sup>, Eric Gibrel Kimbally-Kaky<sup>b</sup>, Paterne Rog Bakekolo<sup>a</sup>, Bertrand Fikhaem Ellenga Mbolla<sup>b</sup>, Meo Stephane Ikama<sup>b</sup>

<sup>a</sup> Department of Cardiology, Teaching University Hospital of Brazzaville, Brazzaville, Republic of Congo

<sup>b</sup> Department of Cardiology, Health Science Faculty, Marien Ngouabi University, Brazzaville, Republic of Congo

### ARTICLE INFO

#### Article history:

Received 14 September 2021

Received in revised form 04 November 2021

Accepted 18 November 2021

Available online 29 November 2021

#### Keywords:

Aortic valve insufficiency

Heart failure

HIV

### ABSTRACT

The human immunodeficiency virus infection is a pathology responsible for chronic inflammation leading to vascular remodeling. We report two cases of patients living with human immunodeficiency virus, with severe aortic insufficiency and dilation of the aorta. Heart failure dominated the clinical signs. The chest x-ray showed cardiomegaly and an enlarged mediastinum. Doppler echocardiography showed, in addition to severe aortic leakage, unusual dilation of the aorta and dissection of the ascending aorta in one of the patients. The computed tomography of the aorta revealed more details about the accuracy and extent of aortic lesions. One of the patients underwent surgical treatment.

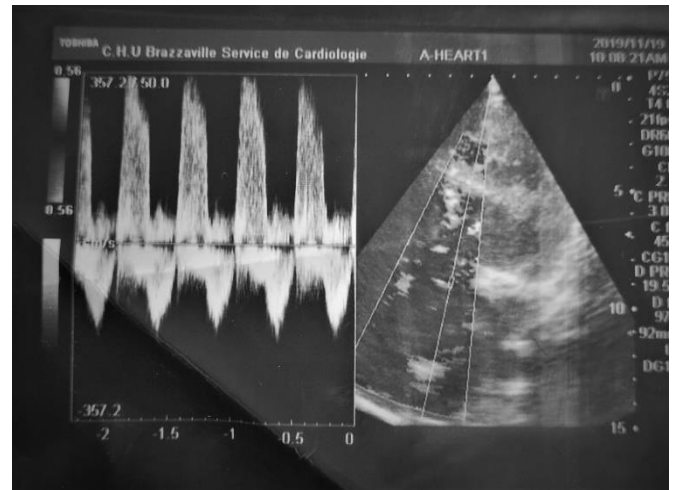
### 1. Introduction

The human immunodeficiency virus (HIV) is responsible for chronic inflammation leading to vascular remodeling.<sup>[1]</sup> Patients infected with HIV are at high risk for cardiovascular disease. The damage occurs by an acceleration of the atherosclerotic process.<sup>[2]</sup> The resulting abnormalities can be cardiac or vascular. Aortic involvement is severe due to its proximity to the heart. Our case report concerns two patients infected with HIV with severe aortic insufficiency and dilation of the ascending aorta, thus raising the question of a coincidence or direct implication of the virus.

### 2. Case presentation 1

A 40-year-old patient without common cardiovascular risk factors was admitted for recurrent heart failure related to severe aortic insufficiency. Clinical examination showed fairly good general condition and signs of congestive heart failure. Heart sounds were regular, with a rate of 96 beats per minute. The presence of a diastolic murmur of aortic insufficiency is estimated at 3/6th. Blood pressure was 100/50 mmHg. The chest x-ray showed cardiomegaly (cardiothoracic ratio [CTR] = 62%), dilated aorta, and interstitial pulmonary edema. The electrocardiogram was in sinus rhythm with left ventricular hypertrophy. Doppler echocardiography showed the ejection fraction of the left ventricle at 74%, dilation of the left heart chambers (left ventricle diameter [LV] = 67.8 mm; left atrium area [LA] = 25 cm<sup>2</sup>), thin and uncalcified heart valves, tricuspid aorta with severe aortic insufficiency

(pressure half-time [PHT] = 188 ms) [Fig. 1], mild functional mitral insufficiency and dilation of the ascending aorta.



**Fig. 1. Doppler Echocardiography shows severe aortic insufficiency.**

Computed tomography of the aorta noted dilation of the ascending aorta (58.5 x 43.2 mm) and descending aorta (40.7 mm) with a fusiform aneurysm [Fig. 2].

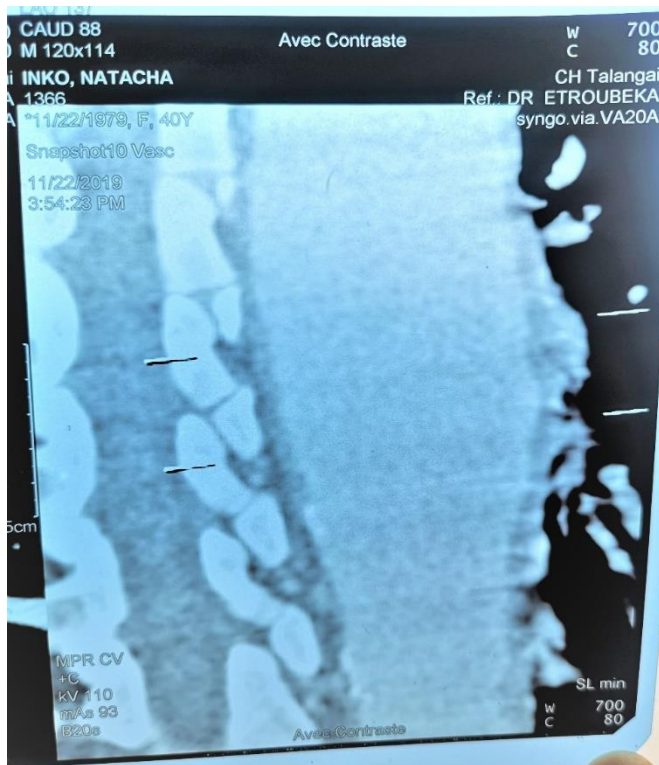
\* Corresponding author. Jospin Karel Makani Bassakouahou

E-mail address: jospinmakani@gmail.com

Department of Cardiology, Teaching University Hospital of Brazzaville, Brazzaville, Republic of Congo

<http://doi.org/10.30485/IJSRDMS.2021.306038.1194>



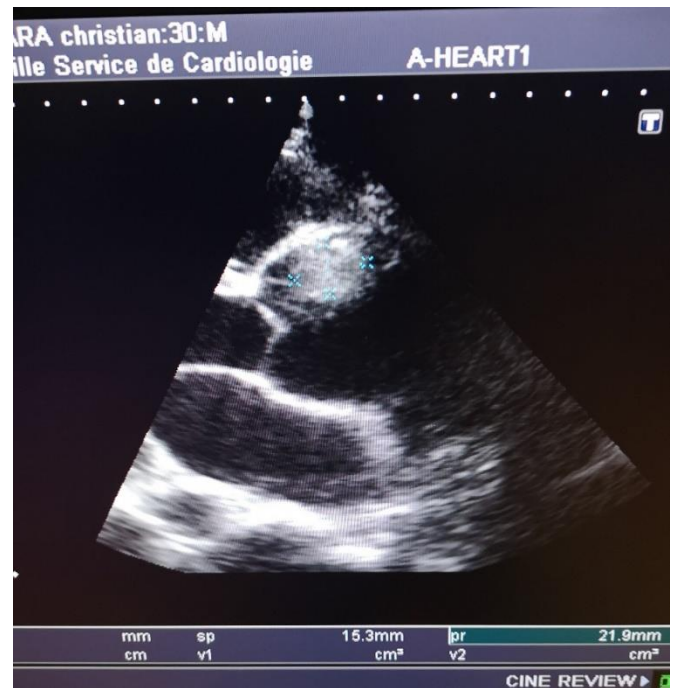


**Fig. 2. Computed tomography shows dilation of the aorta with a fusiform aneurysm.**

The HIV serology was positive. The CD4 cells count was 322/mm<sup>3</sup>; the viral load was unavailable. The sedimentation rate was high at 150 mm. VDRL and TPHA syphilitic serologies were negative. Moderate renal failure with glomerular filtration rate (GFR) at 32 ml/min. The retained diagnosis was severe aortic insufficiency due to dilation of the aorta in an HIV patient. The patient underwent aortic valve replacement with a satisfactory short-term postoperative outcome. On the medical level, besides the treatment of heart failure, antiretroviral therapy by anti-integrase was a retained option due to renal failure.

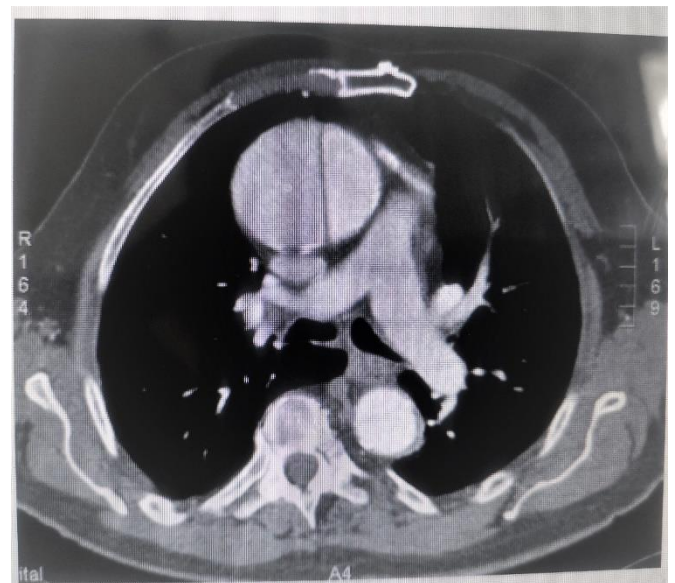
### Case Presentation 2

A 30-year-old HIV patient, without common cardiovascular risk factors, treated for pulmonary tuberculosis was admitted to managing heart failure. Clinical examination showed a deterioration of the general condition, signs of global heart failure, heart sounds were regular with tachycardia at 105 beats per minute. Presence of a proto-diastolic galloping noise and a diastolic murmur of aortic insufficiency estimated 3/6th. The blood pressure was 109/50 mmHg. Peripheral pulses were asymmetric in the upper limbs. The chest x-ray showed cardiomegaly (cardiothoracic ratio [CTR] = 69%), dilated aorta, and pulmonary alveolo-interstitial edema. The electrocardiogram was in sinus rhythm with left ventricular hypertrophy. Doppler Echocardiography showed reduced left ventricular ejection fraction (LVEF= 30%), dilation of the four heart chambers (left ventricle [LV] = 79 mm, right ventricle [RV] = 32 mm, left atrium [LA] = 25 cm<sup>2</sup>, right atrium [RA] = 23 cm<sup>2</sup>), a dilation of the ascending aorta (aortic diameter = 51 mm), the presence of an intimal flap and partial thrombosis of the false channel [Fig. 3].



**Fig. 3. Echocardiography showing partial thrombosis in ascending aorta.**

The heart valves appeared normal. The aorta was tricuspid with severe aortic insufficiency (pressure half-time [PHT] = 192 ms). Computed tomography of the aorta noted abnormal dilation of the ascending and descending aorta with a Stanford type A dissection [Fig. 4].



**Fig. 4. Computed tomography shows a dilation and aortic dissection.**

VDRL and TPHA syphilitic serologies were negative. The CD4 cells count was 90/mm<sup>3</sup> and 450 copies/ml of the viral load. The diagnosis of severe aortic insufficiency by aortic dissection and dilation of the aorta in HIV patients was retained. Surgical treatment was not considered in these hemodynamic conditions. Medical treatment consisted of managing heart

failure and antiviral therapy, including two nucleoside inhibitors and one non-nucleoside inhibitor. However, the vital prognosis remains compromised due to the high mortality risk.

### 3. Discussion

Chronic and systemic inflammation caused by HIV infection is responsible for vascular fragility. It induces an acceleration of the atherosclerotic process.<sup>[1, 2]</sup> It can therefore result in vasculitis and, in particular, an aortic dilation.<sup>[3]</sup> The risk is the occurrence of aortic dissection and an aortic insufficiency due to the absence of coaptation of the aortic sigmoid.<sup>[4-6]</sup> However, these two mechanisms can be combined. The severity of aortic valve damage varies, ranging from minimal to severe aortic leakage with repercussions on the chambers and cardiac function. In our two patients, aortic dilation, aneurysm, and aortic dissection were associated with severe aortic leakage. In addition, it is not uncommon to note aortic dystrophy related to early pathological aging of the aortic structures.<sup>[7]</sup> The latter is the consequence of an excessive inflammation known as "accelerated inflammation" of the HIV patient. Also, this phenomenon is mostly observed if the patient has a high number of associated cardiovascular risk factors, thus influencing life expectancy. Physical exercise and calorie restriction have been described as reducing this phenomenon of oxidative stress.<sup>[1]</sup> However, the absence of common cardiovascular risk factors in our patients raises the possibility of direct involvement of HIV in the occurrence of aortic remodeling or simple coincidence with subclinical cardiovascular risk factors, which can accelerate the atherosclerosis process and require special tools of detection or related to probable elastic tissue disease. Finally, the risk of heart failure is even greater if the patient does not receive effective antiretroviral therapy.<sup>[8, 9]</sup>

### 4. Conclusion

HIV infection is a risky condition for aortic damage. Although of varying severity, Aortic involvement requires special attention due to the proximity of the aorta to the heart. It is, therefore, necessary to screen for it systematically in all patients living with HIV, even in the absence of warning signs. The fight against modifiable cardiovascular risk factors would bring significant benefits, in particular the practice of physical exercise and calorie restriction, which have been described as capable of reducing the phenomenon of oxidative stress in seropositive patients.

### Conflict of Interest

The authors declared that there is no conflict of interest.

### Acknowledgements

This research received no specific grant from any funding agency in the public, commercial, or not-for-profit sectors.

### References

- [1] Leclercq P, Grenoble CH. L'infection VIH: une maladie chronique inflammatoire. *Med Mal Infect.* 2010;40:1-6.
- [2] Mirza H, Patel P, Suresh K, Krukenkamp I, Lawson WE. HIV disease and an atherosclerotic ascending aortic aneurysm. *Reviews in cardiovascular medicine.* 2004;5(3):176-81.
- [3] Lucas ML, Binotto Í, Behar P, Erling N, Lichtenfels E, Aerts N. Thoracoabdominal Aortic Aneurysm in a HIV-positive Patient. *Brazilian journal of cardiovascular surgery.* 2017;32(1):53-6. <https://doi.org/10.21470/1678-9741-2016-0045>.
- [4] Konin C, Amani A, Koffi J. dissection aortique et infection a vih, une association rare observee a l'institut de cardiologie d'abidjan (ICA). *Rev. Int. Sc. Méd.* Vol. 2009;11(2):72-4.
- [5] Moh DR, Badjé A, Ello NF, N'takpé JB, Anzouan-Kacou JB, Kouamé GM, et al. Dissection aortique anévrismale chez un adulte infecté par le VIH-1 dans le cadre d'un syndrome de reconstitution immune avec tuberculose. *Pan African Medical Journal.* 2018;31(1). doi:10.11604/pamj.2018.31.10.12824.
- [6] Silvestri V, D'Ettorre G, Borrazzo C, Mele R. Many different patterns under a common flag: aortic pathology in HIV—a review of case reports in literature. *Annals of vascular surgery.* 2019;59:268-84. <https://doi.org/10.1016/j.avsg.2019.01.016>.
- [7] Jacomet C, Illes G, Kwiatkowski F, Vidal M, Mrozek N, Aumeran C, et al. Prevalence of aortic valve dystrophy and insufficiency in a cohort of 255 HIV-positive patients followed-up in a cardiology department between 2012 and 2014. *International journal of cardiology.* 2016;220:82-6. <https://doi.org/10.1016/j.ijcard.2016.06.237>.
- [8] Butt AA, Chang CC, Kuller L, Goetz MB, Leaf D, Rimland D, et al. Risk of heart failure with human immunodeficiency virus in the absence of prior diagnosis of coronary heart disease. *Archives of internal medicine.* 2011;171(8):737-43. doi:10.1001/archinternmed.2011.151.
- [9] Anzouan-Kacou JB, Dogoua P, Konin C, Coulibaly I, Ouattara I, Eholié SP, ET AL. Affections cardio-vasculaires chez les patients à sérologie VIH positive non traités par anti-rétroviraux. *Cardiovascular diseases in HIV patients not receiving antiretroviral therapy. Cardiologie tropicale.* 2013;131:1-7.

**How to Cite this Article:** Bassakouahou JKM, Landa CMK, Kimbally-Kaky EG, Bakekolo PR, Ellenga-Mbolla BF, Ikama MS. Aortic Remodeling and Human Immunodeficiency Virus Infection: Two Case Reports. *International Journal of Scientific Research in Dental and Medical Sciences*, 2021;3(4):190-192. <http://doi.org/10.30485/IJSRDMS.2021.306038.1194>.