



Periodic Acid Schiff Reactions and General Tissue Morphology of Conventionally-processed versus Two Rapid Microwave-processed Tissues

Anthony Ajuluchukwu Ngokere¹, Tobias Peter Pwajok Choji^{2*},
Samuel Ifedioranma Ogenyi¹, Peterside Rinle Kumbish², Gyang Davou Moses²,
James Saidu Ahmed², Isa Suleiman², Ruth Idzi Zamfara³,
Simon Mshelbwalaa Bukar⁴ and Victoria Davou Gwong⁵

¹Department of Medical Laboratory Science, Nnamdi Azikiwe University, Nnewi Campus, Nigeria.

²National Veterinary Research Institute, Vom, Plateau State, Nigeria.

³Federal College of Veterinary and Medical Laboratory Technology, Vom, Plateau State, Nigeria.

⁴Medical Laboratory Science Council of Nigeria, Yaba, Lagos State, Nigeria.

⁵Plateau State College of Health Technology, Zawan, Plateau State, Nigeria.

Authors' contributions

This work was carried out in collaboration between all authors. All authors read and approved the final manuscript.

Article Information

DOI: 10.9734/BJAST/2016/19710

Editor(s):

(1) Selvakumar Subbian, Laboratory of Mycobacterial Pathogenesis and Immunity, Public Health Research Institute (PHRI) at Rutgers Biomedical and Health Sciences, Newark, USA.

Reviewers:

(1) Marcel Kap, Josephine Nefkens Institute, The Netherlands.

(2) Anonymous, Himachal Pradesh University, India.

(3) Anonymous, University of California San Diego, USA.

(4) Harita Hashim, Universiti Teknologi Mara, Malaysia.

Complete Peer review History: <http://sciencedomain.org/review-history/11567>

Original Research Article

Received 24th June 2015
Accepted 27th August 2015
Published 27th September 2015

ABSTRACT

Aims: To utilise the laboratory microwave as an instrument for a faster, cheaper and reliable tissue processing in the paraffin technique, to establish a processing schedule that eliminates xylene and replace it with a suitable alternative. To check the effect of microwave processing techniques on glycogen reactions as well as tissue morphology.

Study Design: Animal acquisition, sacrifice, harvesting and fixation of tissues. Grossing into triplicates, processing using three different techniques namely the conventional paraffin wax

*Corresponding author: E-mail: tobiasppchoji@gmail.com;

method, the microwave without vacuum method and the microwave with vacuum method. Staining using the PAS-Diastase as well as Haematoxylin and eosin staining techniques. Assessment and grading of morphology and staining characteristics.

Place and Duration of Study: Apparently healthy rabbits from the animal house, National Veterinary research Institute, Vom, Jos, Nigeria, between August and December, 2014.

Methodology: Two apparently healthy rabbits were sacrificed. The lungs, heart, liver, kidney, stomach, and spleen of each were harvested and fixed in 10% buffered formalin for three days. They were grossed into triplicates, labeled and processed using the conventional, microwave without vacuum and microwave with vacuum respectively. They were sectioned and stained simultaneously using the PAS-Diastase as well as H & E staining techniques. They were graded as excellent if they permitted microscopy, fair if not very good but can permit microscopy and poor if they cannot permit microscopy at all. Statistical data generated were processed using one way analysis of variance (ANOVA) at 95% confidence interval.

Results: Processing cycle as well as quantity of reagent used per cycle is greatly reduced in the microwave techniques. Tissue morphology, special features as well as glycogen were clearly demonstrated without significant differences. Dye uptake as well as section thickness were comparable among the three techniques. Block durability is comparable among the three techniques after 64 weeks of storage. There was no statistically significant difference in details of microscopic assessment/quality of tissue preservation ($P=.90$) and details of microscopic assessment/quality of staining ($P=.74$).

Conclusion: Same-day turn-around is possible in histology, with reduced reagent consumption and elimination of xylene, without compromising section quality, dye uptake or the reactions of glycogen in the PAS-Diastase technique. This will result to quick diagnosis hence quick intervention at a cheaper rate to both laboratories and clients. It is a good innovation in forensic and diagnostic histopathology and should be encouraged. Its compatibility with other histochemical techniques, immunohistochemical and molecular techniques should be evaluated to give a wider application.

Keywords: Tissue processing; duration; reagent consumption; glycogen storage disease; PAS-diastase; tissue morphology; microwave; vacuum.

1. INTRODUCTION

The foundation of all good histological preparations is adequate fixation and good tissue processing. Sections cut from poorly processed tissue blocks show poor resistance to the rigors of antigen retrieval techniques and are easily lost. Morphology is impaired and antigens may be lost or become diffused. For almost 100 years, the steps followed to prepare tissues for microscopic review have remained practically unchanged. Substantial shortcomings associated with that practice include at least a 1- day delay in providing the diagnosis, reagent toxicity, and degradation of nucleic acids [1]. However, microwave radiation seems to overcome some of these problems [2]. Microwave-based processing methods have not gained widespread acceptance despite the fact that they are faster and cheaper than the conventional method. The microwave techniques also eliminate the use of toxic chemicals like xylene. Xylene substitutes, either limonene reagents or short chain aliphatic hydrocarbons (alkanes), are rapidly gaining popularity. When substituting these solutions for xylene during processing, it is necessary to

evaluate and possibly adjust the exposure times, number of stations and replacement schedules. The alcohol immediately preceding a xylene substitute *must* be anhydrous. Aliphatic hydrocarbons penetrate specimens faster and remove fat more effectively than xylene. They are very gentle and do not cause hardening of the tissue. They are low in toxicity and reactivity, and considered nonirritating and nonsensitizing. They are, however, completely intolerant of water and require careful handling in high humidity areas [2]. They can be used for processing and staining techniques [3]. The basic aim in any field of life sciences is to utilize eco-friendly chemicals which are nontoxic, less bio-hazardous, and economical [4]. Analytical accuracy, health and safety and cost-efficiency are major concerns in modern pathology laboratories. Isopropanol is less toxic than xylene. The use of isopropanol during dehydration and paraffinization of tissues simplifies and accelerates the process of histological processing. It excludes treatment with intermediate solvents of paraffin (chloroform, xylene, and benzene), which reduces tissue condensation, provides its greater plasticity in cutting and allows obtaining thin serial sections

[5]. Periodic acid–Schiff (PAS) is a staining method used to detect polysaccharides such as glycogen, and mucosubstances such as glycoproteins, glycolipids and mucins in tissues. The reaction of periodic acid oxidizes the vicinal diols in these sugars, usually breaking up the bond between two adjacent carbons not involved in the glycosidic linkage or ring closure in the ring of the monosaccharide units that are parts of the long polysaccharides, and creating a pair of aldehydes at the two free tips of each broken monosaccharide ring. The oxidation condition has to be sufficiently regulated so as to not oxidize the aldehydes further. These aldehydes then react with the Schiff reagent to give a purple-magenta color. A suitable basic stain is often used as a counterstain. Periodic acid–Schiff-Diastase (PAS-D) is PAS stain used in combination with diastase, an enzyme that breaks down glycogen. Alcian blue/periodic acid–Schiff (AB/PAS or AB-PAS) uses alcian blue before the PAS step [6]. PAS staining is mainly used for staining structures containing a high proportion of carbohydrate macromolecules (glycogen, glycoprotein, proteoglycans), typically found in connective tissues, mucus, the glycocalyx, and basal laminae. PAS staining can be used to assist in the diagnosis of several medical conditions:

- Glycogen storage disease (versus other storage disorders).
- Adenocarcinomas, which often secrete neutral mucins.
- Paget disease of the breast.
- Alveolar soft part sarcoma.
- Staining macrophages in Whipple's disease.
- It can be used to diagnose α 1-antitrypsin deficiency if periportal liver hepatocytes stain positive.
- Aggregates of PAS positive lymphocytes are present in epidermis in Mycosis fungoides and Sezary syndrome, called Pautrier microabscesses.
- Ewing Sarcoma
- Erythroleukemia, leukemia of immature red blood cells. These cells stain a bright fuchsia.
- Pulmonary alveolar proteinosis.
- Fungal infection, the cell walls of fungi stain magenta; this only works on living fungi. In contrast, Grocott's methenamine silver stain (GMS) will stain both living and dead fungal organisms.

- It is used to identify glycogen in lung biopsy specimens of infants with pulmonary interstitial glycogenosis (PIG).
- It can be used to highlight super cross-linked lipids inclusions in ceroid lipofuscinosis (NCL).

Presence of glycogen can be confirmed on a section of tissue by using PAS-Diastase method: Here, two sections, 'A' and 'B' are dewaxed and hydrated simultaneously. A is then incubated in diastase so as to digest the glycogen while B remains in water. After the digestion of glycogen in A, the two slides are stained simultaneously using the PAS technique. With this treatment, section A will show 'empty' spaces that were previously occupied by glycogen while section B will show areas of glycogen deposition picking the magenta colour of the Schiff reagent. If the PAS stain will be performed on tissue, the recommended fixative is 10% neutral-buffered formalin or Bouin solution. For blood smears, the recommended fixative is methanol. Glutaraldehyde is not recommended because free aldehyde groups may be available to react with the Schiff reagent, which may result in false positive staining.

2. MATERIALS AND METHODS

Two apparently healthy rabbits [7] aged 8 weeks (weaner) and 48 weeks (adult rabbit) respectively, were sacrificed after chloroform anesthesia [8]. Dissection was performed via one median and two transverse (behind the rib arc) incisions of the soft abdominal wall to expose the viscera in the thoracic and extrathoracic parts [9]. The liver, kidney, stomach, heart, lungs and spleen were immediately harvested (after a careful observation of their gross morphology in order to rule out any macroscopic abnormality) from each of the rabbits and fixed in 10% buffered formalin for three days:

2.1 Tissue Grossing

- The fixed tissues were transferred to the fume cabinet and observed for any macroscopic abnormality.
- The tissues were each cut in triplicates using a sharp scalpel blade in a one stroke action, to sizes of 10 mm X 5 mm X 2 mm and labeled 'C', 'W' and 'V'.
- Each of the individual group tissues were placed in tissue cassettes and labeled appropriately

- Each group (C, W and V) were placed in 10% buffered formalin, labeled appropriately and kept ready for processing.

2.2 Tissue Processing

Tissues in the C category were placed in running tap water for 5 minutes, dehydrated (by passing through ascending grades of ethanol as follows: 70%, 80%, 90%, 95%, Absolute ethanol I, II and III, cleared (in two changes of Xylene) and infiltrated (in two paraffin wax ovens placed at 4°C above the melting point of the paraffin wax used). The SPIN tissue processor, STP 120 (Thermoscientific) was used in which the tissues were subjected to each stage for 2 hours making a total of 22 hours. The 'W' category of tissues were processed using the Tissue Wave™ 2 microwave processor (Thermo Scientific®, Kalamazoo, MI) in which they were first washed with tap water for five minutes and then dehydrated in two changes of absolute ethanol at 67°C for 15 minutes. [10]. The tissues were then passed through two changes of isopropanol at 67°C for 15 minutes each. They were then transferred to preheated paraffin wax and infiltrated at 70°C in the wax for 30 minutes, all at atmospheric pressure, making a total of one hour, thirty minutes. The 'V' category of tissues was processed in the same manner as those for W except that the infiltration was done in a vacuum at a pressure of 20Hg for 20 minutes making a total of 1 hour, 20 minutes. While each of the 12 stations used for the conventional method used 1.8 Ltrs of the reagent, the 6 steps in the microwave techniques used 2 Ltrs each. Reagents used in the microwave processor were filtered using Whatman No.1 filter paper and reused as the need arises.

2.3 Tissue Embedding

At the end of each procedure, the tissues were embedded using embedding cassettes on a tissue Tek Embedding Centre (SLEE MPS/P2), and cooled rapidly on the cooling component as follows:

- tissues were removed from tissue cassettes and placed on the embedding chamber
- Molten paraffin wax was dispensed to full capacity into Tissue Tek embedding mould by pressing the tap backward.
- A Tissue cassette was labeled appropriately with the tissue label being prepared for embedding.

- Using a preheated forceps, the each tissue was picked and orientated in the molten paraffin wax in the mould.
- The cover of the labeled cassette is removed and the reverse side of the cassette is placed on the mould containing the tissue embedded in paraffin wax.
- The embedded mould is now placed on the cooling chamber and allowed to cool and solidify.
- This was repeated for individual tissues until all tissues were embedded.
After a period of 10minutes, the block is detached from the mould (now containing the tissue embedded in the solidified wax).
- Excess wax was trimmed using a scalpel blade.
- They were observed for retraction.

2.4 Tissue Sectioning

- Tissue blocks were attached to the block holder of a rotary microtome (MICROM HM340E ThermoScientific) and trimmed to expose the tissue.
- Tissues were simultaneously placed on ice (tissue side downward) and left for 10minutes.
- Tissue blocks were each returned to the block holder of the microtome and sectioned at three microns (3µm).
- Each section obtained was placed on 20% ethanol to flatten before floating on a floating-out bath.
- They were each picked using albuminised slides, placed at 90° and picked at 45°.
- Sections were dried by placing them vertically and when dry, they were placed on the hot plate (section side uppermost) set at a temperature of 4°C above the melting point of the paraffin wax used, to fix.

The smoothness and ease of sectioning was assessed. The paraffin blocks were stored in a polythene bag and observed for retraction of the tissue daily, for a period of thirty days.

2.5 Tissue Staining

Triplicate sections (one from each of the three processing methods used) of each tissue were simultaneously stained by the (H&E) method for general tissue structure and the PAS with diastase technique [11].

All chemicals used in this study were purchased from S. A Madaki (Nigeria) Enterprises, office 13, Maichibi street, Jenta, P.O. Box 13348, Jos, Plateau State, Nigeria.

2.6 General Criteria for Evaluation of Quality of Sections

The following criteria were used [12,13] to evaluate the three processes:

2.6.1 Section preparation

Cutting texture of blocks, Uniformity of blocks, Cohesiveness of blocks, ribboning & compression during cutting.

2.6.2 Microscopic assessment

- i. **Physical quality of section (excludes stain quality):** this was checked to assess disruption, adhesion, cracking and section thickness [14].
- ii. **Quality of tissue preservation: this was used to assess nuclear and**
 - a. **cytoplasmic details**, special features, (kidney-basement membrane definition, liver-sinusoidal endothelium definition), extracellular components and muscle (collagen, elastin), uniformity of preservation (includes zonal fixation) [15].
 - b. **Quality of staining (chemical):** uniformity, nuclear and cytoplasmic details, as well as extracellular components & muscle (collagen, elastin) were checked and graded. For cellular morphology evaluation, greater eosinophilia of cytoplasm producing enhancement of the nuclear-cytoplasmic contrast, good stroma, whether secretory products are appreciable, red cell lysis absent, whether differentiation can be made between cells and other components of the tissue [16,17].

2.6.3 Scoring criteria

The slides were randomly numbered and circulated among three experienced observers (Observers A, B and C) for blind study and scoring as described by Boon et al. [12] and Ayala et al. [13]. The following scores (see Appendix I) were attached and the average used for statistical analysis:

- i. Excellent: Tissue clearly demonstrated. Most suitable for microscopy (Numerical Value 2)
- ii. Fair: Tissues not very well demonstrated, but can be used for microscopy (Numerical Value 1)
- iii. Poor: Tissue not clearly demonstrated. Not good for microscopy (Numerical Value 0)

2.7 Statistical Analysis

Average scores obtained from three observers, (using a three point scale) were subjected to one way Analysis of Variance (ANOVA) at 95% confidence interval ($H_0: C = W = V$) to determine whether there is a significant difference among the three methods of processing. P -values less than 0.05 were considered significant.

3. RESULTS AND DISCUSSION

Duration per cycle was observed to be drastically reduced in the microwave tissue techniques as it took an average of 85 minutes while the conventional method took 22 hours. Reagent consumption, which is the major determinant for the cost of processing, is seen to be low in the microwave techniques-while xylene is completely eliminated in the microwave techniques, the conventional method consumes over 3 Ltrs of xylene. Only 2 Ltrs of ethanol was used per cycle for the microwave techniques while the conventional method used over 10, Ltrs of ethanol. Isopropanol which is less toxic as compared with xylene and has the ability to complete dehydration if not completely achieved in the ethanol stage was used for dehydration in the microwave techniques. Blocks from the three techniques show no retraction after 64 weeks of observation. There was no discrimination in tissue texture as evident with smooth and uniform sectioning in the three techniques. There is no statistically significant difference among the three techniques (Table 1) in terms of uniformity of staining, nuclear stain, cytoplasmic stain, and extracellular components & muscle (collagen, elastin) ($P=.90$). Also, the nuclear detail, cytoplasmic detail, special features, uniformity of preservation (includes zonal fixation) and appearance of intercellular spaces (Table 2), all presented without a statistically significant difference among the three techniques ($P=.74$).

Sections adhere to glass slides without difficulty and there was no section detachment during

staining. The degree of glycogen digestion with diastase as well as the periodic acid Schiff reaction (without diastase) was comparable among the three techniques (Fig. 1). This has shown that the three techniques do not have a negative chemical effect on glycogen hence can all be use for the study of glycogen-storage diseases. General tissue morphology, staining intensity and demonstration of other substances like basement membrane was also comparable among the three techniques. Stained and mounted slides showed no colour change after 64weeks of storage hence the result of this work shows that there is no change in chemical composition of the tissues in relation to the

commonly used mountant, D.P.X (Destrene, Plasticizer and Xylene).

The microwave is gaining more popularity among clinics and laboratories due to the advantages derived from its usage. In this work, tissues of 2mm maximum thickness were used and the results so far are comparable among the three processing techniques. Since human and larger animal tissues may require a thicker tissue for the same purpose, further work can be done using 3 mm thickness with the same timing as in this experiment and compared with a separate schedule where the timing may be increased to 20 minutes per station.

Table 1. Average scores for details of microscopic assessment/quality of tissue preservation using a simple three point scale for each parameter (2, 1, or 0, with zero being a fail)

Parametre	Group C	Group W	Group V
nuclear detail	1.3	1.7	1.7
cytoplasmic detail	1.3	1.7	1.3
special features	1.7	1	1.3
extracellular components and muscle	1.3	1	1.7
uniformity of preservation (includes zonal fixation)	2	2	2
appearance of intercellular spaces	1.7	1.7	2

Anova: Single Factor

Summary				
Groups	Count	Sum	Average	Variance
Group C	6	9.3	1.55	0.087
Group W	6	9.1	1.51	0.173
Group V	6	10	1.66	0.098

ANOVA

Source of Variation	SS	df	MS	F	P-value	F crit
Between Groups	0.0744	2	0.037	0.31	0.738	3.6823
Within Groups	1.7967	15	0.12			
Total	1.8711	17				

Table 2. Average scores for details of microscopic assessment/quality of staining using a simple three point scale for each parameter (2, 1, or 0, with zero being a fail)

Parametre	Group C	Group W	Group V
uniformity of staining	2	2	2
nuclear stain	1.3	1.3	1.3
cytoplasmic stain	2	2	2
extracellular components & muscle (collagen, elastin)	1.3	1.7	1.7

Anova: Single factor

Summary				
Groups	Count	Sum	Average	Variance
Group C	4	6.6	1.65	0.1633
Group W	4	7	1.75	0.11
Group V	4	7	1.75	0.11

ANOVA

Source of variation	SS	df	MS	F	P-value	F crit
Between Groups	0.0267	2	0.0133	0.1043	0.902	4.2565
Within Groups	1.15	9	0.1278			
Total	1.1767	11				

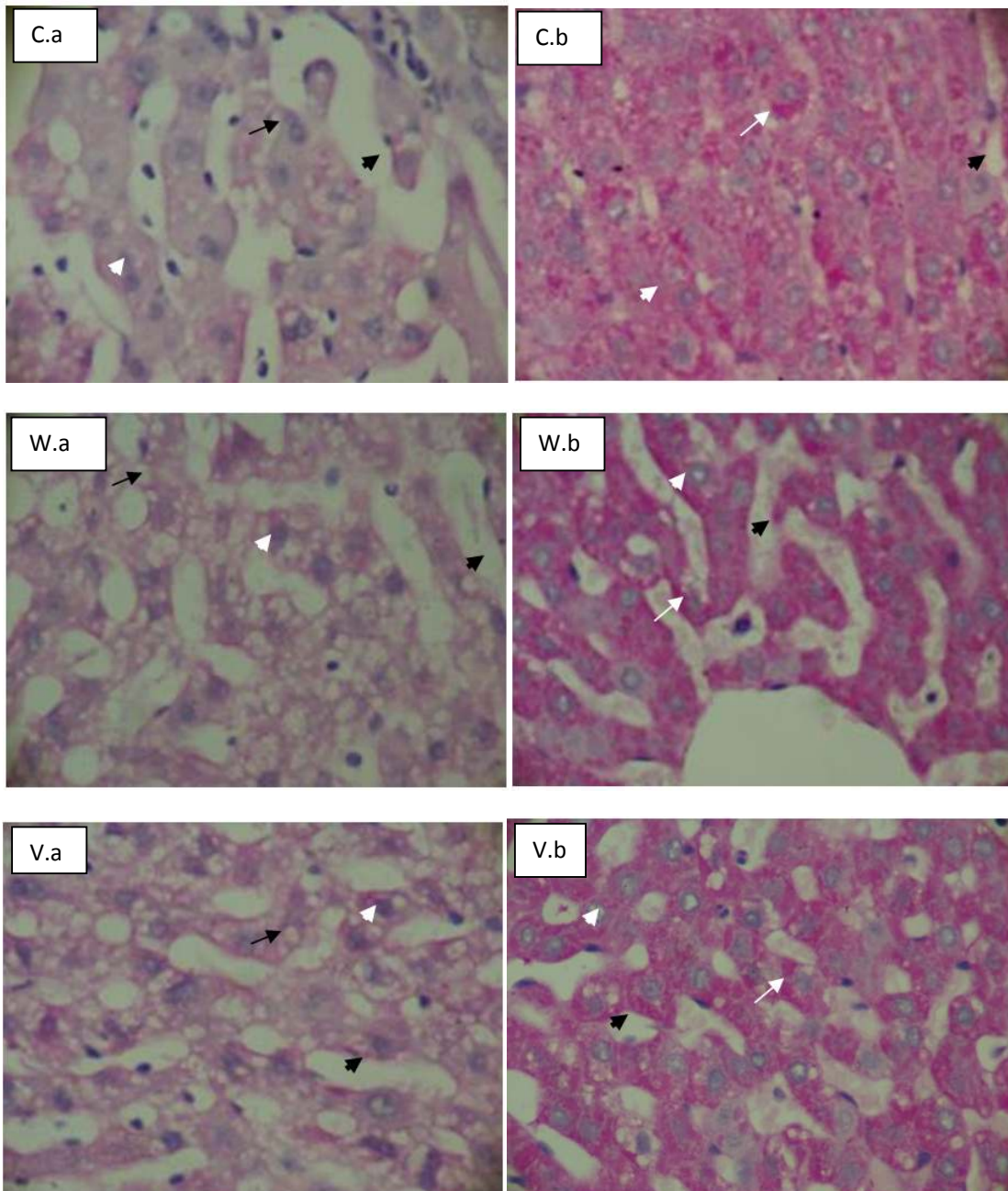


Fig. 1. Liver of a weaner processed using the three techniques and stained using the Periodic acid Schiff reaction with diastase (PAS-D) (Plate 1Ca, Wa and Va) and PAS without diastase (Plate 1Cb, 1Wb and 1Vb). Glycogen deposits are observed to be digested and the space appears empty in PAS-D (black arrows) while glycogen deposits are clearly demonstrated (white arrows) in PAS without Diastase. Nuclei (white arrowheads) and sinusoids (black arrowhead) are clearly demonstrated in the three techniques

Note: C=Conventional, W=Microwave without vacuum, V=Microwave with vacuum, a= sections treated with diastase, b=sections not treated with diastase. All images of PAS and PAS-D-stained sections were photographed at X400 magnification

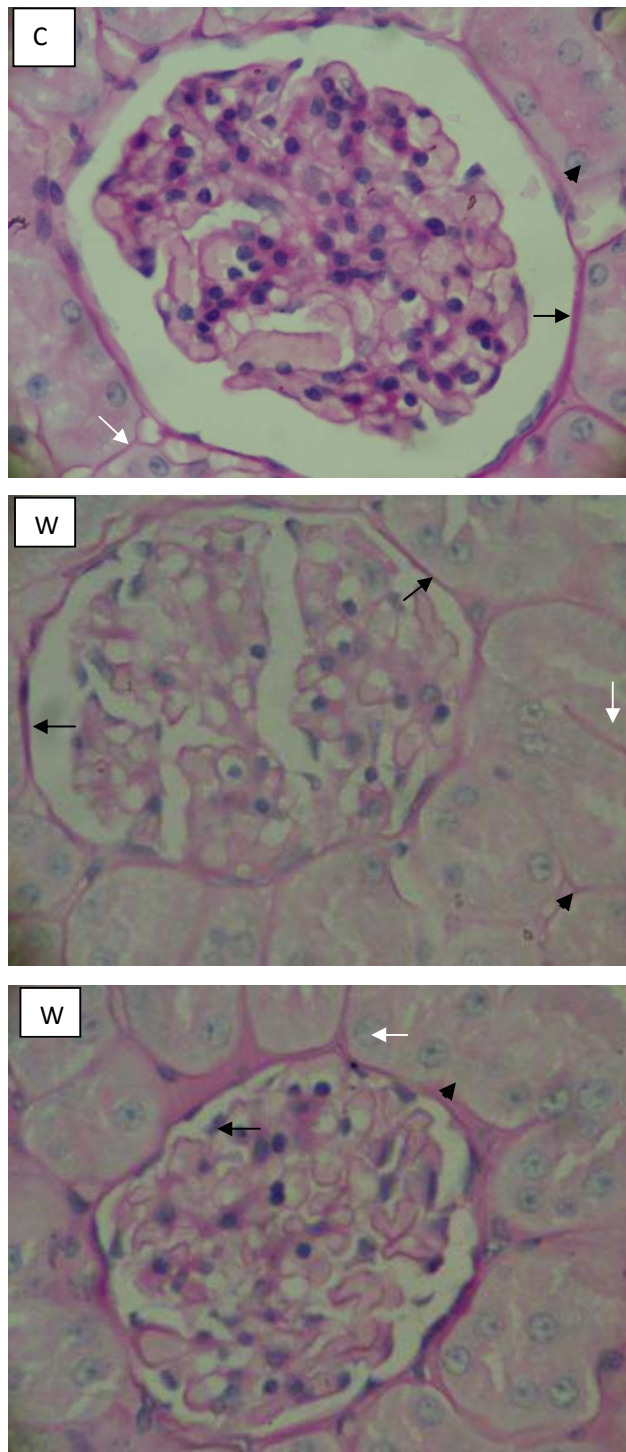


Fig. 2. Kidney glomerulus of adult rabbit processed using the three techniques. Glomerular capsule (black arrows) and basement membranes (white arrows) and glycogen pick their characteristic pinkish colour in which this technique is known for. The conventional method presented a sharper staining characteristic. Nuclei (black arrowhead) stain bluish. All images of PAS-stained sections were photographed at X 400 magnification

Note: C=Conventional, W=Microwave without vacuum, V=Microwave with vacuum

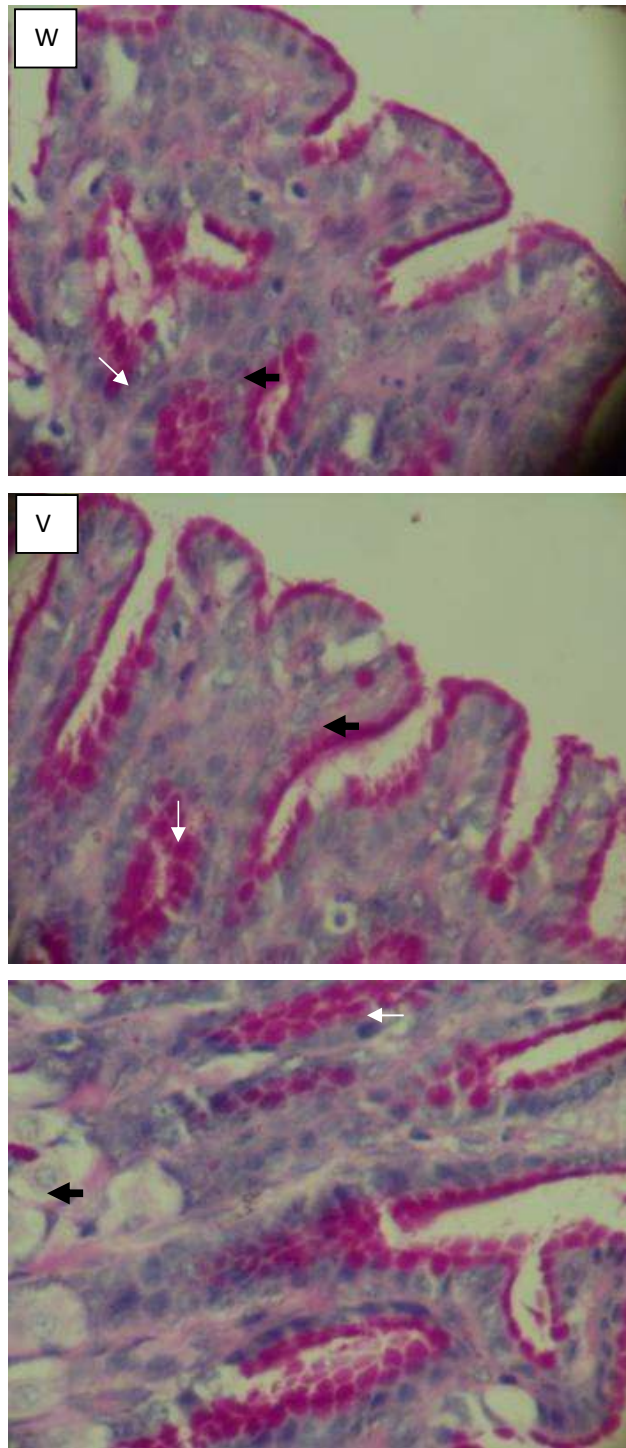


Fig. 3. Stomach gastric mucosa of a weaner demonstrating the mucus-secreting cells (white arrows). Mucus-secreting cells are special features that pick magenta with PAS stain. Nuclei (black arrows). This characteristic is retained in the three techniques as seen above. PAS without diastase staining technique. All images of PAS-stained sections were photographed at X 400 magnification

Note: C=Conventional, W=Microwave without vacuum, V=Microwave with vacuum

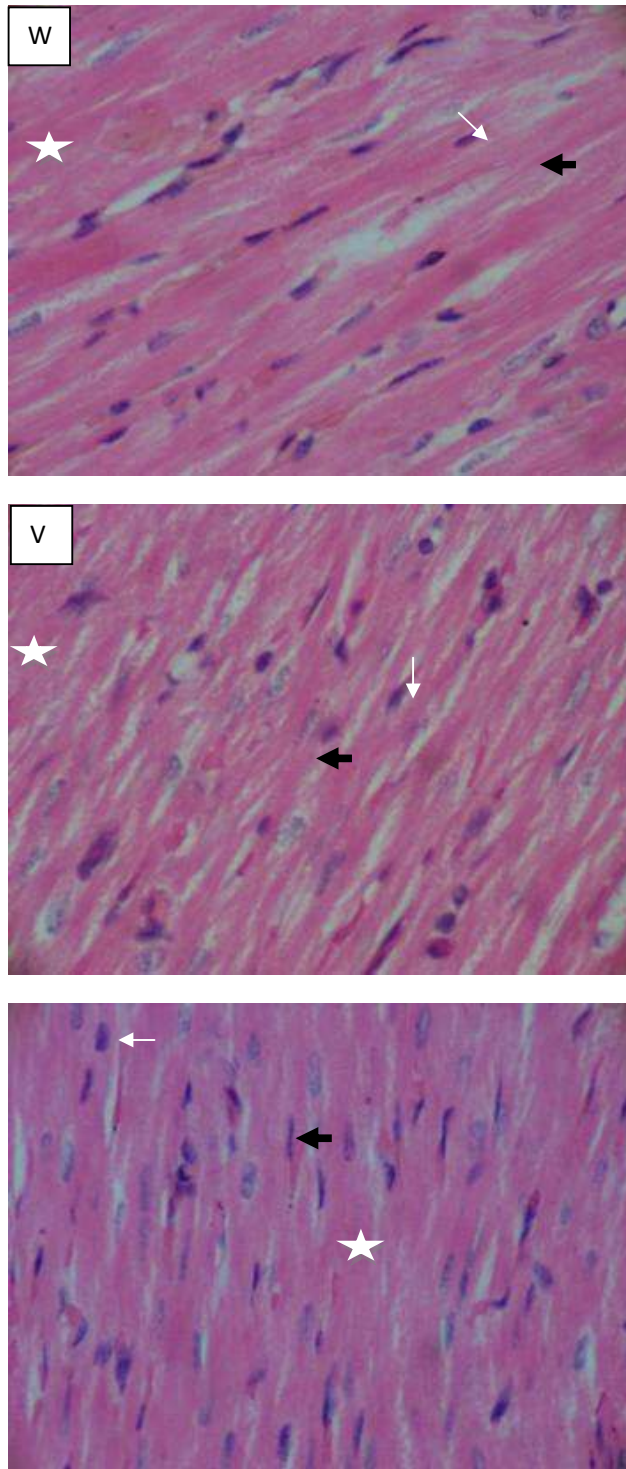


Fig. 4. Heart of a rabbit processed by the three techniques. Characteristic pinkish staining of cardiac muscle (white stars) and bluish staining of the nuclei (white arrows) is demonstrated clearly in the three techniques. Black arrows= muscle striation. All images of H&E-stained sections were photographed at X 400 magnification

Note: C=Conventional, W=Microwave without vacuum, V=Microwave with vacuum

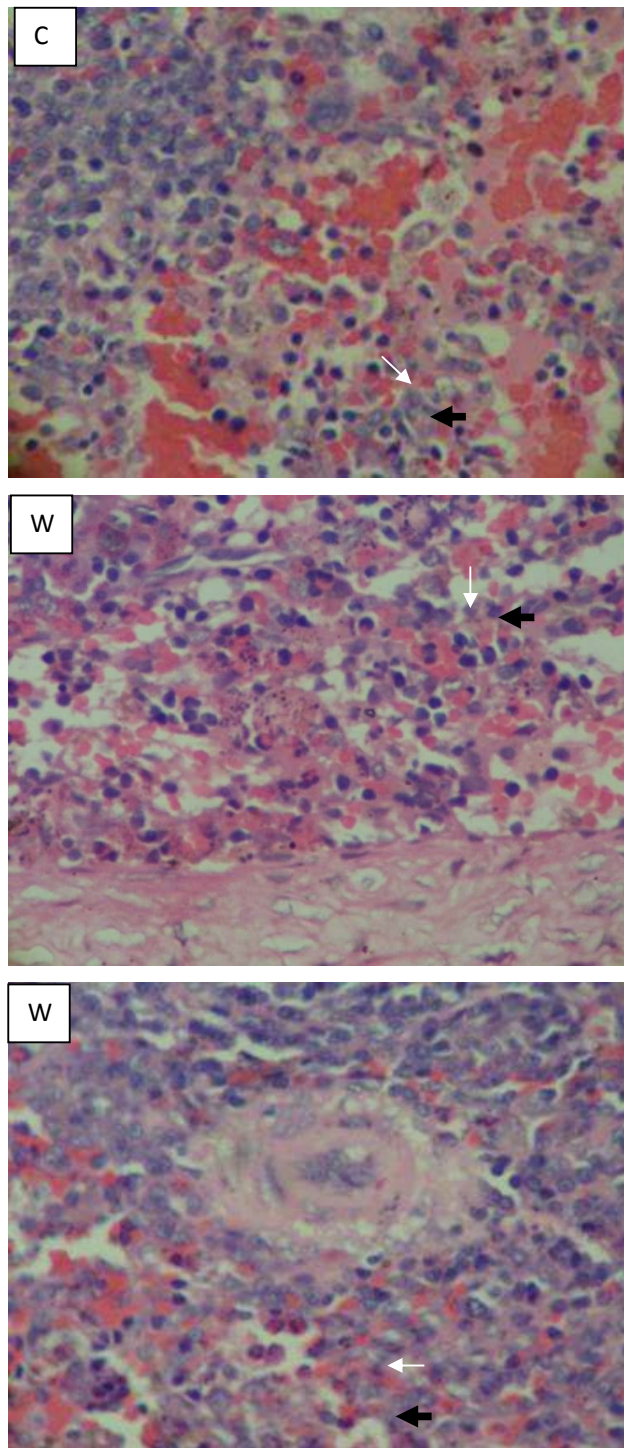


Fig. 5. Spleen of an adult rabbit processed by the three techniques showing intact splenic cells with comparable staining characteristic among the three techniques. Splenic cords in red pulp (black arrows) are seen interspersed by red blood cells (white arrows). All images of H&E -stained sections were photographed at X 400 magnification

Note: C=Conventional, W=Microwave without vacuum, V=Microwave with vacuum

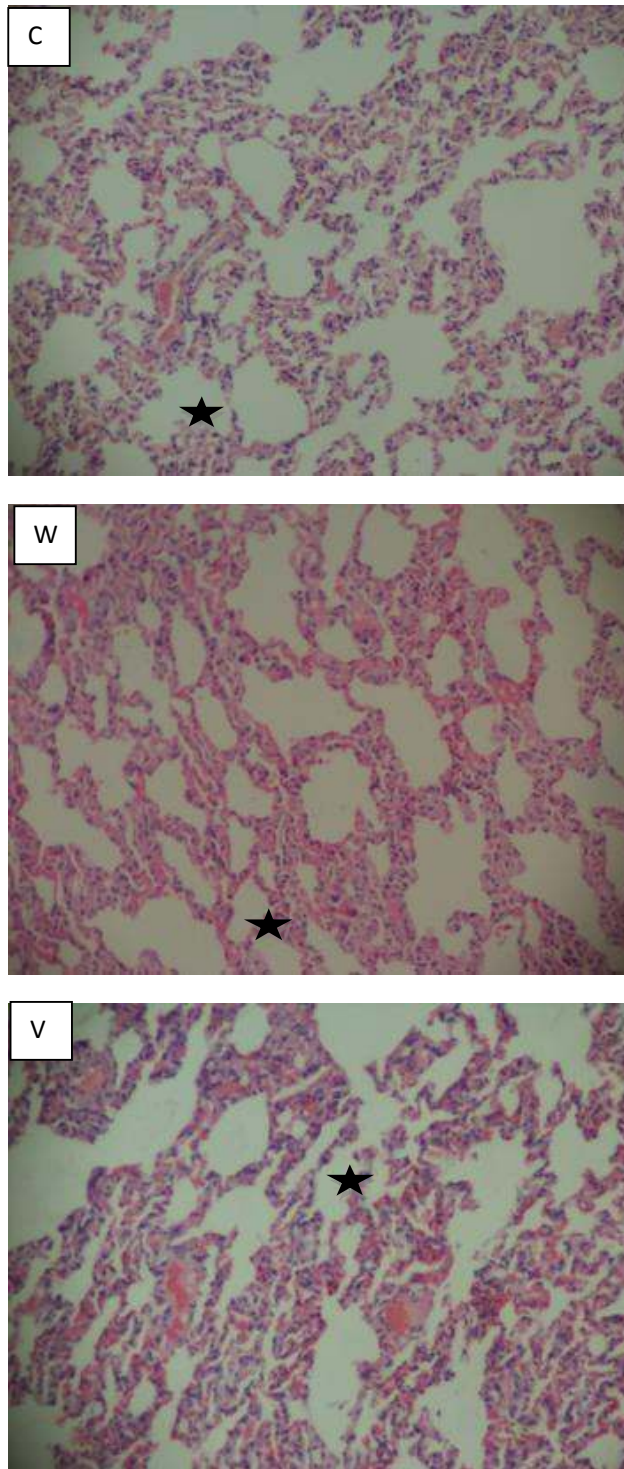


Fig. 6. Adult rabbit lung tissue processed by the three techniques. The characteristic bluish staining of the nuclei and pinkish staining of the cytoplasm is clearly demonstrated in the three techniques. Black stars= alveolar spaces. All images of H&E-stained sections were photographed at X400 magnification

Note: C=Conventional, W=Microwave without vacuum, V=Microwave with vacuum

4. CONCLUSION

This work shows that histology samples can be processed in less than two hours with and sections obtained retaining comparable quality in terms of morphology and/or PAS-D reaction quality. Xylene, with its deleterious effect on both the tissue and the laboratorian, has now been eliminated from the processing schedule without compromising tissue quality. The quantity of alcohol used for dehydration is also reduced in the microwave techniques. Isopropanol, which is miscible with both paraffin wax and ethanol and has the ability to complete dehydration, can now be properly utilized in tissue processing. Very long processing schedules have been known to have deleterious effect on the tissue as it results to tissue shrinkage, excessive hardening that results to crumbling of tissues during sectioning as well as retraction of tissues stored in the blocks [18,19]. The microwave techniques retain the tissue for a very short time as compared to the conventional methods hence these negative effects are now eliminated.

This work shows that same day turn-around is possible in histology laboratory without compromising tissue morphology, or the reaction of PAS positive substances. The microwave techniques are also cheaper than the conventional method hence patient care can be made cheaper if this techniques are utilized. This work agrees with other authors [10,14]. This technique can be utilized in institutions where electricity supply is erratic as tissue processing can be carried out within a very short time. Where electricity supply is interrupted, it is convenient to remove the 'load' and continue the processing in another system, unlike the conventional method which does not permit the removal of the tissues during periods of power outage. Packaging of histology samples for further investigations like forensic investigation, immunohistochemistry and molecular analysis can be made faster. Tissue processed using the microwave techniques should be subjected to these advance techniques so as to have a wider application.

5. LIMITATION

This work is limited to tissues of 2 mm maximum thickness. If tissue of greater thickness is to be processed on the microwave, the duration per station can be increased, say to 20 minutes and results compared with those of 15 minutes per station.

COMPETING INTERESTS

Authors have declared that no competing interests exist.

REFERENCES

1. Lewis F, Maughan NJ, Smith V, et al. Unlocking the archive: Gene expression in paraffin-embedded tissue. *J Pathol.* 2001;195:66-71.
2. Morales AR, Essenfled H, Essenfled E, Duboue MC, Vincek V, Nadji M. Continuous-specimen-flow, high throughput, 1-hour tissue processing. *Arch Pathol Lab Med.* 2002;126:583-590.
3. Goldstein NS, Ferkowicz MT, Odish E, Mani A, Hastah F. Minimum formalin fixation time for consistent estrogen receptor immunohistochemical staining of invasive breast carcinoma. *Am J Clin Pathol.* 2003;120:86-93.
4. Ankle MR, Joshi PS. A study to evaluate the efficacy of xylene-free hematoxylin and eosin staining procedure as compared to the conventional hematoxylin and eosin staining: An experimental study. *J Oral Maxillofac Pathol.* 2011;15(2):161-7.
5. Viktorov IV, Proshin SS. Use of isopropyl alcohol in histological assays: Dehydration of tissue, embedding into paraffin, and processing of paraffin sections. *Bulletin of Experimental Biology and Medicine.* 2003;136(7):119-20.
6. Carson FL, Hladik, C. *Histotechnology: A Self-Instructional Text.* 3rd ed. Hong Kong: American Society for Clinical Pathology. 2009;137-39.
7. Grizzle WE. The effect of tissue processing variables other than fixation on histochemical staining and immunohistochemical detection of antigens. *J Histotechnol.* 2001;24:213-19.
8. Berghes C, Parvu M, Cuca D. Anatomic studies about rabbit spermatics ways. *Lucrări științifice Zootehnie și Biotehnoologii.* 2009;42(1).
9. Hristov H, Kostov D, Vladova D. Topographical anatomy of some abdominal organs in rabbits. *Trakia Journal of Sciences.* 2006;4(3):7-10.
10. Awwioro OG. Staining reactions of microwave processed tissues compared with conventional paraffin wax processed tissues. *Eur. J. Exp. Bio.* 2011;1(1):57-62.
11. Awwioro OG. *Histochemistry and tissue pathology, principle and techniques.* 1st ed.

- Claverianun Press. Ibadan, Nigeria. 2002;175-206.
12. Boon ME, Kok LP, Noordam EO. Microwave - stimulated diffusion for fast processing of tissue: Reduced dehydrating, clearing and impregnating times. *Histopathology*. 1986;10:303-309.
 13. Ayala E, Enghardt MH, Horton M. Cost effective, environmentally safe tissue processing method with paraffin oil. *J Histotechnol*. 1997;20(2):133-37.
 14. Chaudhari K, Chattopadhyay A, Dutta SK. Microwave technique in histopathology and it's comparison with the conventional technique. *J Histotechnol*. 2000;43(4):387-94.
 15. Leong AS. Microwave irradiation in histopathology. *Pathology Annual*. 1998; 23:213-233.
 16. Rolls GO, Farmer NJ, Hall JB. Artifacts in histological and cytological preparations. 1st edition. Melbourne. 2008: Leica Microsystems.
 17. Warmington AR, Wilkinson JM, Riley CB. Evaluation of ethanol-based fixatives as a substitute for formalin in diagnostic clinical laboratories. *J Histotechnol*. 2000;23(4): 299-308.
 18. Beusa RJ, Peshkov MV. Histology Without xylene. *Ann Diagn Pathol*. 2009;13:246–256. Kandyala R, Raghavendra SC, Rajasekharan ST. Xylene: An overview of its health hazards and preventive measures. *J Oral Maxillofac Pathol*. 2010;14:1-5.
 19. Emerson LL, Tripp SR, Baird BC, Layfield LJ, Rohr LR. A comparison of immunohistochemical stain quality in conventional and rapid microwave processed tissues. *Am J Clin Pathol*. 2006;125(2):176-83.

© 2016 Ngokere et al.; This is an Open Access article distributed under the terms of the Creative Commons Attribution License (<http://creativecommons.org/licenses/by/4.0>), which permits unrestricted use, distribution, and reproduction in any medium, provided the original work is properly cited.

Peer-review history:
The peer review history for this paper can be accessed here:
<http://sciencedomain.org/review-history/11567>