



Exophthalmos Revealing Malignant Lymphoma

**Z. Hazil ^{a*}, A. Krichen ^a, I. Hasnaoui ^a, S. Hassina ^a,
Y. Akannour ^a, L. Seghini ^a, Z. Hajji ^a, B. Ouazzani ^a
and E. Abdallah ^a**

^a Department of Ophthalmology B, Rabat Specialty Hospital, CHU ibn Sina, Mohammed V Souissi University Rabat, Morocco.

Authors' contributions

This work was carried out in collaboration among all authors. All authors read and approved the final manuscript.

Article Information

DOI: 10.9734/OR/2024/v19i3421

Open Peer Review History:

This journal follows the Advanced Open Peer Review policy. Identity of the Reviewers, Editor(s) and additional Reviewers, peer review comments, different versions of the manuscript, comments of the editors, etc are available here: <https://www.sdiarticle5.com/review-history/115350>

Case Study

Received: 29/01/2024

Accepted: 04/04/2024

Published: 13/04/2024

ABSTRACT

Non-Hodgkin's lymphomas are malignant tumors whose aggressiveness depends on the histological type of the tumor. The orbital localization may be isolated or associated with a systemic lymphoma.

The clinical polymorphism of malignant lymphomas is extreme, posing diagnostic problems and delaying therapeutic management, which is why anatomopathological examination of a tissue biopsy is the only key to diagnosis.

We report the case of a patient who presented with exophthalmos revealing a lymphoma.

Keywords: *Exophthalmos; non-hodgkin's lymphoma; malignant proliferations.*

*Corresponding author: E-mail: zahira.hazil@gmail.com;

1. INTRODUCTION

Non-Hodgkin's lymphomas (NHL) are monoclonal malignant proliferations of B or T lymphoid cells at various stages of maturation. They usually develop in lymph node territories. Primary extra-nodal localization accounts for less than a third of cases. Orbital localization is rare, and mainly occurs in adults. The most frequent warning sign is exophthalmos. Malignancy is suspected on the basis of clinical and radiological criteria, but only histology confirms the diagnosis.

2. CLINICAL CASE

This is a case of an old female patient with no specific pathological history who presented with a left exophthalmos that had been evolving for 20 days. Visual acuity was preserved, the anterior

segment was normal and the FO showed macular folds. After 3 days, the exophthalmos progressed towards exaggeration and the appearance of local inflammatory signs (Fig. 1).

An orbito-cerebral CT scan revealed an intraconal tissue process in the left orbit measuring 34*21 mm, responsible for stage 3 exophthalmos with no overt signs of aggressiveness, suggestive of a possible lymphoma (Fig. 2).

Tumour biopsy and pathological study showed the presence of T-type NHL. The extension work-up was negative and the lymphoma was classified as stage I. Induction chemotherapy followed by radiotherapy was indicated after patient consent.

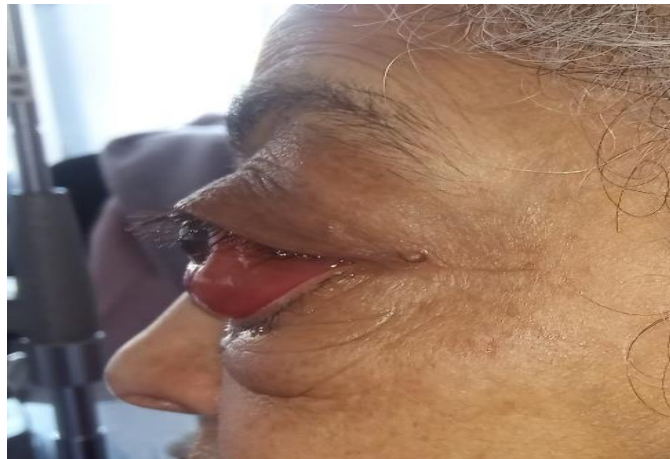

Fig. 1. Profile photograph of exophthalmos with inflammatory signs in the left eye

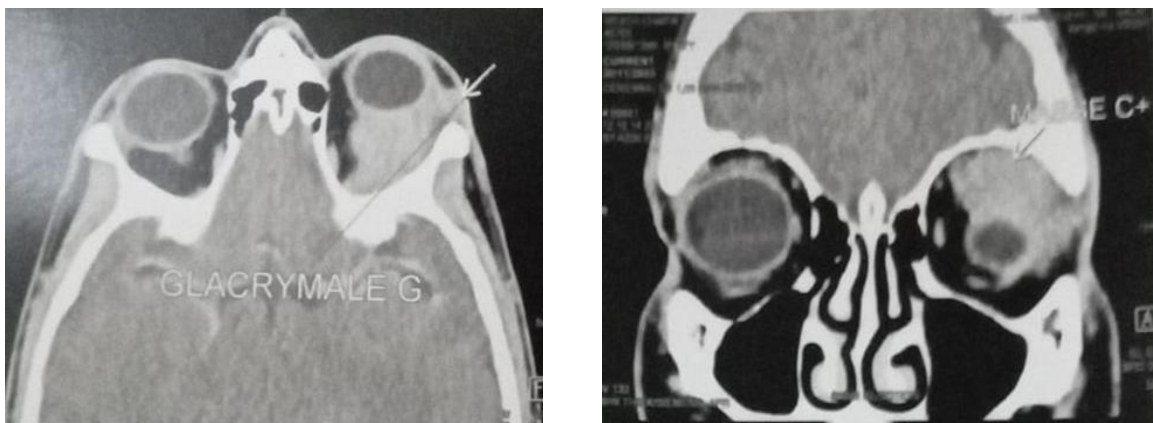


Fig. 2. Scans showing an intraconal tissue process in the left orbit measuring 34*21 mm, responsible for stage 3 exophthalmos with no overt signs of aggressiveness

3. DISCUSSION

Orbital lymphomas account for 8% of orbital tumours [1] and less than 1% of all non-Hodgkin's lymphomas [2]. They may be isolated, as in our patient's case, or associated with a systemic lymphoma. Lymphomas of the orbit and adnexa affect the eyelids in 5-21% of cases, the conjunctiva in 21-33% or the orbit in 46-74% [2,3].

These lymphomas mainly affect adults [4,1]. Clinical presentation is highly variable, depending above all on the site of development and the aggressiveness of the disease. Exophthalmos is the most frequent warning sign in cases of posterior development [5]. The diagnosis is suspected on the basis of clinical and radiological findings, but is only confirmed by anatomopathological examination of the tumour biopsy [4]. This histological examination also enables the lymphoma to be typed, thus helping in the choice of treatment protocol. Among lymphomas of the orbit and adnexa, 30-50% present or will present a systemic lymphoma [6,7,8], hence the interest of an extension work-up involving the superficial and deep lymph node areas, the bone marrow, the cerebrospinal fluid in high-grade forms of malignancy, and other organs depending on the presenting signs [9]. Analysis of the results of the extension work-up and general work-up enables lymphoma to be classified according to the Ann Arbor classification, which will guide treatment and predict the prognosis of the disease.

Treatment depends on the degree of malignancy of the tumor, its aggressiveness and whether or not there is a systemic lymphoma:

- For isolated low-grade orbital lymphoma: radiotherapy alone (30 Gy in 20 sessions over 4 weeks).
- In case of isolated high-grade orbital lymphoma: 3 cycles of CHOP induction chemotherapy followed by radiotherapy of 30 Gy in 20 sessions in case of complete response to chemotherapy, and 36 to 40 Gy in 20 sessions in case of partial response.
- In the case of lymphoma with systemic invasion: polychemotherapy under the supervision of an oncologist.

In the case of aggressive lymphomas, a combination of chemotherapy and radiotherapy

is indicated, given that the relapse rate is fairly high after radiotherapy alone (9 to 20%) and that the survival rate is better in the case of a combination. This chemotherapy makes it possible to deliver lower doses of radiotherapy [2,6,10,11,7,8].

Local control of orbital lymphomas by radiotherapy is excellent, ranging from 89% to 100%, with a distant metastasis rate of 0-25% for high-grade lymphomas and 5% of low-grade lymphomas [4].

The prognosis depends on the anatomopathological characteristics of the tumour (type T, poor prognosis), the size of the tumour mass (extension work-up+++ [12] and the patient's condition. However, this prognosis can be improved by early management [13].

4. CONCLUSION

Orbital lymphoma is a tumour characterized by extreme clinical polymorphism, which can lead to misdiagnosis and delayed therapeutic management. Diagnosis is based on anatomopathological examination of the lesion. Treatment depends on the type and stage of the lymphoma, and includes radiotherapy preceded or not by induction chemotherapy in the case of stage I-II, and polychemotherapy in the case of systemic lymphoma.

CONSENT

As per international standards or university standards, patient(s) written consent has been collected and preserved by the author(s).

ETHICAL APPROVAL

As per international standards or university standards written ethical approval has been collected and preserved by the author(s).

COMPETING INTERESTS

Authors have declared that no competing interests exist.

REFERENCES

1. Ben Zina Z. et coll. Lymphome orbitaire isolée chez l'enfant. A propos d'un cas. La Tunisie Médicale. 2004 ;82(09):717-724.
2. Bhatia S, Arnold C, Paulino MD, John M, Buatti MD, Nina A, Mayr MD, B -Chen Wen MD. Curative radiotherapy for primary

- orbital lymphoma. *Int. J. Radiation Oncology Biol. Phys.* 2002;54(3):818-823.
3. Carol L, Jerry A, Shields MD, Cynthia Carvalho MD, Paul Rundle MD, Andrew F, Smith PhD. Conjunctival lymphoid tumors. Clinical analysis of 117 cases and relationship to systemic lymphoma. *Ophtalmology.* 2001;108(5):979-984.
 4. Abdelouahed K, Laghmari M, Tachfouti S, Cherkaoui W, Khorassani M, Aloui M'seffer F, Mohcine Z. Leucémie aigue lymphoblastique T/Lymphome lymphoblastique orbitaire chez l'enfant. *J Fr. Ophtalmol.* 2005;28(2):197-200.
 5. Bracaglia. Upper and lower lid fatty herniation: An unusual presentation of non Hodgkin's lymphoma. *British Journal of Plastic Surgery.* 2003;56.
 6. Christopher E, Richard B, Wilder Chul S, Mark A, Fernando F, James D Cox. Clinical stage IEA – IIEA orbital lymphomas: Outcome in the era of modern staging and treatment. *Radiotherapy and Oncology.* 2001;59(2):145-151.
 7. Rykers K, al. Orbital lymphoma: A simple treatment using electrons. *Medical Dosimetry.* 2003;28(2):95-98.
 8. Scott L, Timothy F Kozelsky, James A Garrity, Paul J Kurtin, Jacqueline A Leavitt, James A Martenson, Thomas M Habermann. Orbital lymphoma: Radiotherapy outcome and complications. *Radiotherapy and Oncology.* 2001;59(2): 139-144.
 9. Bella-Hiag AL, Ebana C, Sede Mbakop. Le lymphome malin orbito-sinusal. A propos d'un cas, *Médecine d'Afrique Noire.* 2000; 47(1).
 10. Conill C, Alberto Sánchez-Reyes MD, Meritxell Molla MD, Antonio Vilalta MD. Brachytherapy with 192Ir as treatment of carcinoma of the tarsal structure of the eyelid. *Int. J. Radiation Oncology Biol. Phys.* 2004;59(5):1326-1329.
 11. Raphael Pleffer M, Tatiana Rabin MD, Lev Tsvang M.Sc., Janna Goffman M.Sc., Nahum Rosen MD, Zvi Symon MD. Orbital lymphoma: Is it necessary to treat the entire orbit. *Int. J. of Radiation Oncology Biol. Phys.* 2004;60(2):527-530.
 12. Moussala M, Mbakop A, Ondoa Mekongo M, Ndonbe P. Late diagnosis of oculo-orbital tumors and traditional medicine in Cameroon. About 2 cases. *Black African Medicine.* 1998;45(1).
 13. Derbel M et al. Exophthalmos and blindness revealing a malignant non-Hodgkin's ethmoido-maxillary T- cell lymphoma. about an observation. *J. Fr. Ophtalmol.* 1999;22(5):566-570.

© Copyright (2024): Author(s). The licensee is the journal publisher. This is an Open Access article distributed under the terms of the Creative Commons Attribution License (<http://creativecommons.org/licenses/by/4.0>), which permits unrestricted use, distribution, and reproduction in any medium, provided the original work is properly cited.

Peer-review history:

The peer review history for this paper can be accessed here:
<https://www.sdiarticle5.com/review-history/115350>