



Evaluation of the Efficacy and Safety of Autologous Adipose Tissue-Derived Stem Cells in Treatment of Keloids

**Aya Ashraf Fouda^{a*}, Naeim Mohamed Abd EL-Naby^a,
Mohamed Atteya Saad^b, Tarek Gamal Shoukr^c and Tarek Al-Sayed Amin^a**

^a *Dermatology and Venereology Department, Faculty of Medicine, Tanta University, Tanta, Egypt.*

^b *Clinical Pathology Department, Faculty of Medicine, Tanta University, Tanta, Egypt.*

^c *Plastic Surgery Department, Faculty of Medicine, Tanta University, Tanta, Egypt.*

Authors' contributions

This work was carried out in collaboration among all authors. All authors read and approved the final manuscript.

Article Information

DOI: 10.9734/JAMMR/2022/v34i234889

Open Peer Review History:

This journal follows the Advanced Open Peer Review policy. Identity of the Reviewers, Editor(s) and additional Reviewers, peer review comments, different versions of the manuscript, comments of the editors, etc are available here: <https://www.sdiarticle5.com/review-history/94501>

Original Research Article

Received 01 October 2022
Accepted 03 December 2022
Published 09 December 2022

ABSTRACT

Background: The formation of keloids is accompanied by undesirable aesthetic and psychological impacts. Different therapeutic techniques, including local injection, occlusive dressings, surgical excision, and lasers have been examined for keloids. This work objects to evaluate the efficacy and the safety of autologous adipose tissue-derived stem cells (ADSCs) in keloids treatment.

Methods: This prospective clinical research involved 15 subjects with keloids who were injected with autologous ADSCs three sessions at monthly intervals. Follow up was done for 3 months after treatment and evaluation was done for improvement in Vancouver scar score, patient's opinion and physician's opinion.

Results: In the studied patients, 8 patients (53.3%) showed good improvement (25 – 49%), 7 patients (46.7%) showed very good improvement (50 – 74%) and none of the patients (0%) showed excellent improvement. Side effects were mild and tolerable and included pain during injection and abdominal discomfort for few days after lipoaspiration.

Conclusions: Adipose-derived stem cells are effective, safe and are of more value in improving consistency and vascularity of keloids.

*Corresponding author;

Keywords: Autologous adipose tissue-derived stem cells; keloids.

1. INTRODUCTION

Keloids are fibroproliferative masses caused by aberrant wound healing, which result from enhanced or reduced control of certain wound healing mechanisms [1]. Stem cell therapy has exhibited considerable promise in the treatment of a wide range of illnesses, including orthopaedic conditions, inflammatory diseases, hepatic failure, and autoimmune conditions [2,3].

Adipose tissue is a good source of autologous adipose tissue-derived stem cells (ADSCs) and is easier to collect, plentiful and has a lesser risk of problems compared to bone marrow derived stem cells (BMSCs), [4]. They possess anti-inflammatory and neoangiogenic properties, release several growth factors, and are capable of developing into several cell types [5].

ADSCs have been implicated in the complex process of wound healing [6] and they work via two distinct processes: First, they suppress the overall inflammatory reaction, and then they change into cells associated with wound repair, such as myofibroblasts, fibroblasts, endothelial progenitor cells and antigen-presenting cells.

Injections of ADSCs at the injury site may enhance healing and lower the chance of scar formation [7]. Human ADSCs may drive scar remodelling via suppressing the impacts of TGF- β 1 on fibroblasts, reducing the production of MMP particles, and lowering mast cell functions [8]. Paracrine inhibition of TGF- β 1-induced activation of human dermal fibroblasts and keloid scar-derived fibroblasts by human ADSCs was observed *in vitro* [9]. The paracrine TGF- β 1 action of ADSCs may decrease the production of type-1 collagen and hyaluronic acid at the mRNA level. It has been found that amplification of TGF- β 1 promotes ECM production, leading to scar formation. ADSCs can affect the biological behavior of keloid fibroblasts *in vitro*, particularly proliferation, migration and ECM formation, by modulating the TGF- β 1/Smad route [10].

This work objects to evaluate the efficacy and the safety of autologous ADSCs in treatment of keloids.

2. PATIENTS AND METHODS

This prospective clinical research involved 15 subjects with keloid scars.

Exclusion criteria were pregnant and lactating females, subjects younger than 12 years old, local infection (bacterial, viral, mycobacterial and fungal) or systemic infective diseases (hepatitis B, hepatitis C, HIV), patients with systemic disease such as renal diseases, hepatic diseases or diabetes mellitus, patients with collagen or autoimmune diseases, panniculitis or any disease affecting fat, very thin patients (body mass index less than 18.5); no donor site for liposuction, any patient suffering from a skin disease with positive Koebner's phenomenon (e.g. psoriasis, lichen planus, vitiligo), history of any blood related disease, drug abuse, smoking, allergic disorder to one of the agents or medications used in present study, past or present history of malignancy, psychiatric illness, patients who had recent treatment of their keloids by any procedure in the previous 6 months and subjects with unreasonable hopes.

Subjects were injected with autologous ADSCs three sessions at monthly intervals.

All subjects underwent full history taking, general examination, calculating body mass index, skin examination, laboratory investigations and blood tests to exclude hepatitis B, hepatitis C and HIV infection. Systemic antibiotic (amoxicillin clavulanic acid) was given before the procedure and continued one week after the procedure for all patients.

2.1 Extraction of Adipose Derived Stem Cells

Lipoaspiration was done under local anesthesia at surgical theatre under complete aseptic precautions. With the case in supine position and the donor site was thoroughly cleaned with povidone-iodine 10%. After achieving a small anesthetic region in the donor area with lidocaine at 2%, an incision is made using blade 11. Tumescence anesthesia was performed. Harvesting fat was performed using 2 or 3 mm, three holes, blunt tip cannula with a 60 ml Luer-lock syringe.

The aspirated fat was kept in the sterile tubes in upright position. Fig. 1 The infranatant tumescent fluid and blood were removed. Lipoaspirate was extensively washed in equal volume with phosphate-buffered saline (PBS). The process of washing was repeated 3-4 times for about 5 minutes each time until the infranatant from the

wash becomes clear. Fig. 2 Adipose tissue was combined with an equivalent amount of collagenase that had been diluted with sterile PBS. 1 g of collagenase was suspended in 10 mL of PBS, and 49 mL of PBS was added to each 1 mL of the resulting solution. The mixture was placed in 50 ml conical tubes in water bath at 37°C for 30 minutes. Every 5-10 minutes, gently stir the collagenase/adipose combination and then return it to the water bath. As digestion continues, the adipose tissue layer should take on a "smoother" look. Fig. 3 The digested fat was allowed to settle then; supernatant was discarded and each 25 ml aliquots of the infranatant having the stromal vascular fraction was placed into sterile 50 ml centrifuge tubes. In each tube containing 25 ml of the infranatant fluid, 25 ml of sterile Control Medium (CM) were added: (For 500 ml of CM, combine the following: 440 ml DMEM (4.5 g/L glucose, with L-glutamine), 50 ml fetal bovine serum (heat inactivated), 5 ml penicillin/streptomycin (10,000 IU penicillin, 10,000 µg/ml streptomycin) and 5 ml amphotericin B (250 µg/ml amphotericin B) may also be added. Sterile filtration of this media is required if non-sterile reagents are used. Place the CM in a 37°C water bath 30 min prior to use to warm the medium. The collagenase was rendered inactive by adding CM and incubated at room temperature for 5 minutes. To collect the SVF as a pellet, it was centrifuged for 10 minutes at 1,200 x g. The supernatant from each tube was aspirated and discarded. Using 30 ml CM, the SVF pellets were mixed in a single centrifuge tube and divided evenly between two fresh 50 ml centrifuge tubes. Second centrifugation was done for 10 min at 1,200 x g and the supernatants from the two SVF pellets were aspirated. Fig. 4 The resuspended SVF pellet was filtered by gravity flow through a 100 m mesh filter placed on top of a fresh 50 ml centrifuge tube. 5 mL of saline solution was then added to the cellular pellet at the bottom of the tube, rendering it suitable for usage.

2.2 Assessment of Patients

Digital photographs were taken before treatment, before each session, 1 month & 3 months after the last session using a digital camera with the same positioning, the same magnification and the same light intensity.

Assessment was done by a 3-physicians committee after completion of the treatment by comparing before-and-after digital photographs, height, color and pliability of keloids. Finally, the mean value of the 3 investigators record was

obtained for each patient according to the quartile grading scale: poor improvement (<25%), good improvement (25-49%), very good improvement (50-74%), excellent improvement (≥75%).

Vancouver Scar Scale (VSS)

Assessment of itching through Verbal Rating Scale (VRS) as follows: [11]

0: Noitch, 1: Mild itch, 2: Moderate itch, 3: Severe itch and 4: Very severe itch

Assessment of pain through Verbal Rating Scale (VRS) as follows: [12]

0: No pain, 1: Slight pain, 2: Moderate pain, 3: Severe pain and 4: Unbearable pain.

2.3 Statistical Analysis

SPSS v25 performed the statistical analysis (IBM Inc., Chicago, IL, USA). Comparing quantitative parametric data reported as mean and standard deviation (SD) for the same group utilizing the paired Student's t-test. Non-parametric quantitative data were given as median and interquartile range (IQR) and examined utilizing Mann-Whitney test. When applicable, qualitative variables were given as frequency and percentage (%) and examined utilizing Chi-square test or Fisher's exact test. Pearson's coefficient of correlation was utilized to do a linear correlation study and assess the positive or negative connection between distinct variables. A two-tailed P value ≤0.05 was statistically significant.

3. RESULTS

There was a significant reduction in the height of keloids after treatment in the studied group (P value <0.001). There was no significant improvement in pigmentation of keloids after treatment compared to before treatment. There was a significant improvement in vascularity and consistency of keloids after treatment in the studied group Table 3.

There was a significant improvement in VSS after treatment than before treatment in the studied group Table 4.

There was no significant correlation among improvement in VSS after treatment with sex of the patients, skin type, site and cause of keloids in both groups.

There was a significant improvement in itching after treatment while there was no significant variance in pain before and after treatment Table 5.

Table 1. Demographic data and skin type of the studied group

		(n = 15)
Sex	Male	7 (46.7%)
	Female	8 (53.3%)
Age (Years)		30.5 ± 5.48
Fitzpatrick skintype	Type III	8 (53.3%)
	Type IV	7 (46.7%)

Data are presented as mean ± SD, median (IQR) or frequency (%)

Table 2. Site and cause of keloids in the studied group

		(n = 15)
Site of keloids	Head and neck	0 (0.0%)
	Chest	8 (53.3%)
	Upper limb	3 (20.0%)
	Lower limb	2 (13.3%)
	Back	1 (6.7%)
	Abdomen	1 (6.7%)
Cause of keloids	Spontaneous	0 (0.0%)
	Post-surgery	0 (0.0%)
	Burn	8 (53.3%)
	Trauma	7 (46.7%)

Table 3. Improvement in height, pigmentation, vascularity and consistency among the studied group

Keloids height	Before treatment	3 (2 – 3)
	After treatment	1 (1 – 2)
	P value	<0.001*
Keloids pigmentation before treatment	Normal	3 (20.0%)
	Hyper pigmentation	12 (80.0%)
Keloids pigmentation after treatment	Normal	6 (40.0%)
	Hyper pigmentation	9 (60.0%)
P value		0.250
Keloids vascularity (color) before treatment	Normal	2 (13.3%)
	Pink	5 (33.3%)
	Purple	6 (40.0%)
	Red	2 (13.3%)
Keloids vascularity (color) after treatment	Normal	2 (13.3%)
	Pink	8 (53.3%)
	Red	5 (33.3%)
P value		0.001*
Keloids consistency (pliability) before treatment	Firm	13 (86.7%)
	Band	2 (13.3%)
Keloids consistency (pliability) after treatment	Normal	0 (0.0%)
	Supple	10 (66.7%)
	Firm	5 (33.3%)
P value		0.032*

Data are presented as median (IQR) or frequency (%). *: significant as P value ≤ 0.05

Table 4. Quartile grading scale and vancouver scar scale of the studied group

		(n = 15)
Quartile grading scale after treatment	Good (25 – 49%)	8 (53.3%)
	Very good (50 – 74%)	7 (46.7%)
	Excellent (75 – 100%)	0 (0.0%)
Vancouver scar scale	Before treatment	8 (8 – 10)
	After treatment	6 (3 – 7)
	P value	0.001*

Data are presented as median (IQR) or frequency (%). *: significant as P value \leq 0.05

Table 5. Improvement in itching and pain among the studied group

		(n = 15)
Itching before treatment	No	0 (0.0%)
	Mild	4 (26.7%)
	Moderate	3 (20.0%)
	Severe	4 (26.7%)
	Very Severe	4 (26.7%)
Itching after treatment	No	2 (13.3%)
	Mild	6 (40.0%)
	Moderate	6 (40.0%)
	Severe	1 (6.7%)
P value		0.013*
Pain before treatment	No	1 (6.7%)
	Slight	5 (33.3%)
	Moderate	5 (33.3%)
	Severe	2 (13.3%)
	Unbearable	2 (13.3%)
Pain after treatment	No	6 (40.0%)
	Slight	8 (53.3%)
	Moderate	1 (6.7%)
	Severe	0 (0.0%)
P value		0.206

Data are presented as frequency (%). *: significant as P value \leq 0.05

4. DISCUSSION

Keloids are distinct fibroproliferative diseases of the wounded human dermis [13].

Klinger et al. [14] reported an enhancement in skin elasticity, texture, and thickness in three cases with hemifacial hypertrophic scars and keloids as a result of severe burns who were injected with adipose tissue extracted from abdomen subcutaneous fat. This improvement is dependent on ADSCs promoting tissue repair, which supports the results of this study where patients treated by injection of ADSCs showed significant improvement in height and skin elasticity after treatment.

In a different study by Klinger et al. [15] with fat grafting performed on hypertrophic scars reported that All treated scars showed a qualitative improvement from a cosmetic and functional standpoint, with a decrease or full

remission of discomfort and an increase in scar flexibility and patient and observer scar evaluation ratings demonstrated statistically significant reductions in all parameters except itching, supporting our findings of statistically significant enhancement in scar pliability, height, and vancouver scar scale but in contrast to our results where itching was significantly improved this discrepancy may be due to the different sample size in both researches and may be due to the frequent injections in the present study.

The outcomes of this research were also supported by Brongo et al. [16] who conducted fat grafting on 18 cases with post-burn hypertrophic scars and keloids, noticing an improvement in colour, texture, elasticity, thickness, and a decrease in scar contraction.

All patients enrolled in this study showed improvement of pain after treatment similarly

Fredman et al. [17] reported improvement of neuropathic pain, color, texture, pliability, contour and pruritus of scars following fat graft.

Carstens et al. [18] reported five cases with mature burn scars were cured with enzymatically separated stromal vascular fraction. Scars were concentrated mostly on the hands, limiting mobility. The most of treated areas enhanced in pigmentation, flexibility, thickness, pruritus, discomfort, and vascularity six months after treatment, and these results are consistent with our results regarding improvement in thickness, flexibility, vascularity and itching which were

improved significantly on the other hand pigmentation and pain were improved but not significantly.

Similar to the present study Lee et al. [19] In a case series of 17 cases (19 scars with a wide range of characteristics, including hypertrophic, depressed, and contractile), those who received stromal vascular fraction injection alone or in conjunction with other procedures reported statistically significant improvement in vascularity, pigmentation, hardness, flexibility, and pliability, also vanceuver scar scale was significantly enhanced in the SVF-treated group.

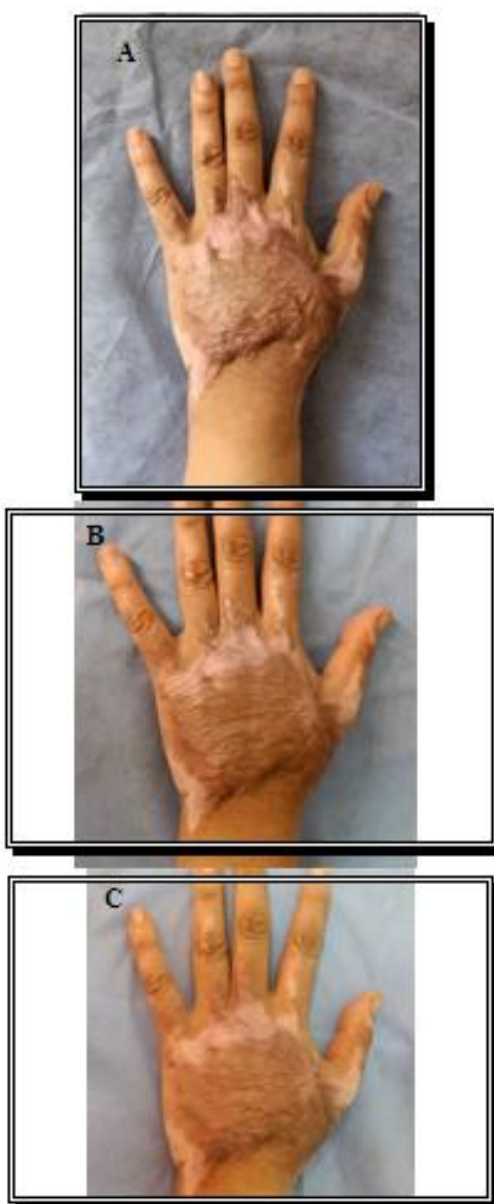


Photo 1. Patient with keloid on hand before treatment (A) after two sessions (B) and after three months follow-up (C) showing over all very good improvement

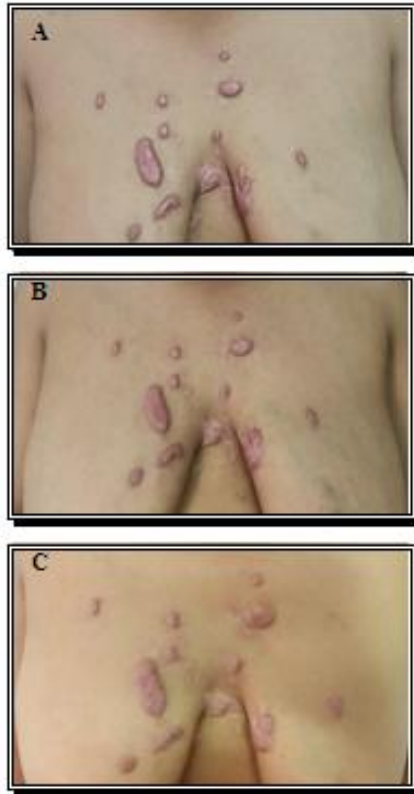


Photo 2. Patient with keloid on chest before treatment (A) after two sessions (B) and after three months follow-up (C) showing over all very good improvement

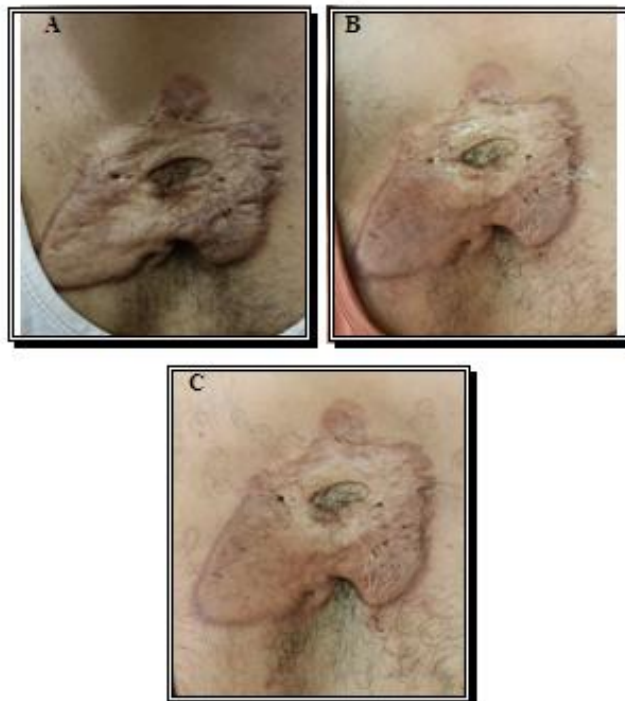

Photo 3. Patient with keloid on chest before treatment (A) after two sessions (B) and after three months follow-up (C) showing over all good improvement

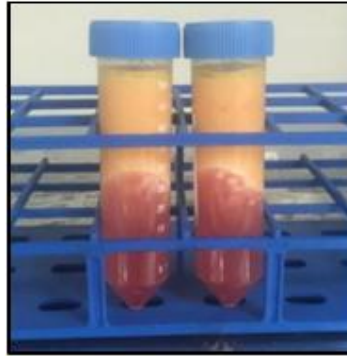


Fig. 1. Collection of the aspirated fat in sterile tubes in upright position

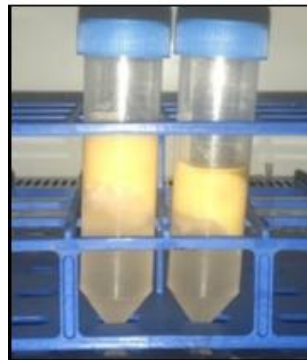


Fig. 2. Washing of the aspirated fat with PBS till the infranatant fluid becomes clear

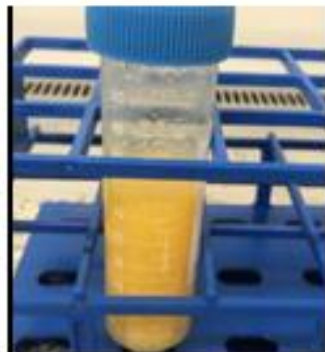


Fig. 3. Aspirated fat after incubation with collagenase became smoother with soup-like appearance



Fig. 4. The cell pellet after second centrifugation

5. CONCLUSIONS

Injection of ADSCs is safe and efficient in treatment of keloids. Adipose-derived stem cells are of value in improving consistency and vascularity of keloids.

CONSENT AND ETHICAL APPROVAL

An informed written consent was obtained from the patient. The research was performed after approval from the Ethical Committee Tanta University Hospitals.

COMPETING INTERESTS

Authors have declared that no competing interests exist.

REFERENCES

- Lee HJ, Jang YJ. Recent understandings of biology, prophylaxis and treatment strategies for hypertrophic scars and keloids. *Int J Mol Sci.* 2018;19.
- Mizuno H. Adipose-derived stem cells for tissue repair and regeneration: ten years of research and a literature review. *J Nippon Med Sch.* 2009;76:56-66.
- Tabatabaei Qomi R, Sheykhasan M. Adipose-derived stromal cell in regenerative medicine: A review. *World J Stem Cells.* 2017;9:107-17.
- Kern S, Eichler H, Stoeve J, Klüter H, Bieback K. Comparative analysis of mesenchymal stem cells from bone marrow, umbilical cord blood, or adipose tissue. *Stem Cells.* 2006;24:1294-301.
- Lauritano D, Palmieri A, Vinci R, Azzi L, Taglabue A, Carinci F. Adipose derived stem cells: basic science fundamentals and clinical application. An update. *Minerva Stomatol.* 2014;63:273-81.
- Demidova-Rice TN, Hamblin MR, Herman IM. Acute and impaired wound healing: pathophysiology and current methods for drug delivery, part 1: Normal and chronic wounds: biology, causes, and approaches to care. *Adv Skin Wound Care.* 2012;25:304-14.
- Zonari A, Martins TM, Paula AC, Boeloni JN, Novikoff S, Marques AP et al. Polyhydroxybutyrate-co-hydroxyvalerate structures loaded with adipose stem cells promote skin healing with reduced scarring. *Acta Biomater.* 2015;17:170-81.
- Yun IS, Jeon YR, Lee WJ, Lee JW, Rah DK, Tark KC, et al. Effect of human adipose derived stem cells on scar formation and remodeling in a pig model: A pilot study. *Dermatol Surg.* 2012;38:1678-88.
- Spiekman M, Przybyt E, Plantinga JA, Gibbs S, van der Lei B, Harmsen MC. Adipose tissue-derived stromal cells inhibit TGF- β 1-induced differentiation of human dermal fibroblasts and keloid scar-derived fibroblasts in a paracrine fashion. *Plast Reconstr Surg.* 2014;134:699-712.
- Jung H, Kim HH, Lee DH, Hwang YS, Yang HC, Park JC. Transforming growth factor-beta 1 in adipose derived stem cells conditioned medium is a dominant paracrine mediator determines hyaluronic acid and collagen expression profile. *Cytotechnology.* 2011;63:57-66.
- Erickson S, Kim BS. Research Techniques Made Simple: Itch Measurement in Clinical Trials. *J Invest Dermatol.* 2019;139:264-9.e1.
- Bech RD, Lauritsen J, Ovesen O, Overgaard S. The Verbal Rating Scale Is Reliable for Assessment of Postoperative Pain in Hip Fracture Patients. *Pain Res Treat.* 2015;2015:676212.
- Tredget EE, Nedelec B, Scott PG, Ghahary A. Hypertrophic scars, keloids, and contractures. The cellular and molecular basis for therapy. *Surg Clin North Am.* 1997;77:701-30.
- Klinger M, Marazzi M, Vigo D, Torre M. Fat injection for cases of severe burn outcomes: a new perspective of scar remodeling and reduction. *Aesthetic Plast Surg.* 2008;32:465-9.
- Klinger M, Caviggioli F, Klinger FM, Giannasi S, Bandi V, Banzatti B, et al. Autologous fat graft in scar treatment. *J Craniofac Surg.* 2013;24:1610-5.
- Brongo S, Nicoletti GF, La Padula S, Mele CM, D'Andrea F. Use of lipofilling for the treatment of severe burn outcomes. *Plast Reconstr Surg.* 2012;130:374e-6e.
- Fredman R, Edkins RE, Hultman CS. Fat Grafting for Neuropathic Pain After Severe Burns. *Ann Plast Surg.* 2016;76 (Suppl 4):S298-303.
- Carstens M, Pérez M, Briceño H, Valladares S, Correa D. Treatment of late sequelae of burn scar fibrosis with adipose-derived stromal vascular fraction (SVF) cells: A case series. *CellR4.* 2017;5:2404.

19. Lee JW, Park SH, Lee SJ, Kim SH, Suh IS, Jeong HS. Clinical Impact of Highly Condensed Stromal Vascular Fraction Injection in Surgical Management of Depressed and Contracted Scars. *Aesthetic Plast Surg.* 2018;42:1689-98.

© 2022 Fouda et al.; This is an Open Access article distributed under the terms of the Creative Commons Attribution License (<http://creativecommons.org/licenses/by/4.0>), which permits unrestricted use, distribution, and reproduction in any medium, provided the original work is properly cited.

Peer-review history:

The peer review history for this paper can be accessed here:
<https://www.sdiarticle5.com/review-history/94501>