

The Ameliorative Effect of *Ginkgo biloba* Supplement on Cyclosporine- A Induced Renal Toxicity in Male Wistar Rat

**Uzoije Nnamdi Nwokoma^a, Lekpa Kingdom David^{a,b*},
Henrietta Ogadimma Asuzu-Samuel^a, Akoko Sokiprim^c
and Precious Ojo Uahomo^{a,c}**

^a Department of Biomedical Technology, School of Science Laboratory Technology, University of Port Harcourt, Nigeria.

^b Department of Anatomy, Faculty of Basic Medical Sciences, University of Port Harcourt, Nigeria.

^c Department of Pharmacology, Faculty of Basic Clinical Sciences, University of Port Harcourt, Nigeria.

Authors' contributions

This work was carried out in collaboration among all authors. All authors read and approved the final manuscript.

Article Information

DOI: 10.9734/JAMPS/2022/v24i130279

Open Peer Review History:

This journal follows the Advanced Open Peer Review policy. Identity of the Reviewers, Editor(s) and additional Reviewers, peer review comments, different versions of the manuscript, comments of the editors, etc are available here: <https://www.sdiarticle5.com/review-history/85049>

Original Research Article

**Received 12 January 2022
Accepted 14 March 2022
Published 24 March 2022**

ABSTRACT

Ginkgo biloba supplement is a flavonoid-rich herbal supplement with several therapeutic potentials. However, the efficacy of *Ginkgo biloba* supplement to protect the kidney and liver against cyclosporine-A induced toxicity is not fully understood. This study is to investigate the effect of *Ginkgo biloba* supplement on Wistar rat induced hepato-renal toxicity. Twenty Wistar rats were randomly selected into four groups containing 5 wistar. Group 1 were given water (vehicle 10ml/kg body weight) and feed, group 2 were induced with Cyclosporine (CsA) (25mg/kg body weight), *Ginkgo biloba* supplement (GBS) (50mg/Kg body weight) was administered to group 3 and group 4 were administered with CsA (25mg/kg body weight) and GBS (50mg/kg body weight) co-administration for 15 days respectively. The animals were then anaesthetized with ketamine (70mg/kg body weight). The blood samples were collected into EDTA bottles for plasma biochemistry while liver and kidney tissues were also harvested and preserved in 10% formalin for histological examination. The data were subjected to descriptive statistics using one-way ANOVA

*Corresponding author: E-mail: lekpadavid@yahoo.com;

and $p < 0.05$ was considered significant. Total protein, Urea and Creatinine were significantly increased when compared with control. Treatment with *Ginkgo biloba* supplement showed reduction of these liver and kidney biomarkers. Total protein was significantly reduced in Cyclosporine induced animals compared to *Ginkgo biloba* supplement treated animals. The weight of the liver and kidney were not significantly different in the animals that received both cyclosporine and *Ginkgo biloba* supplement. There was a histological alteration in liver and kidney tissues following cyclosporine induction. However, *Ginkgo biloba* supplement restored normalcy to these tissues. In conclusion, this study suggests that *Ginkgo biloba* supplement protected the liver and kidney against cyclosporine induced hepato-renal toxicity and this is attributed to the presence of flavonoids.

Keywords: *Ginkgo biloba* supplement; cyclosporine-A; kidney biomarkers; toxicity.

1. INTRODUCTION

Cyclosporine-A (CsA), a strong immunosuppressive drug derived from a fungal endecapeptide, is widely used to extend the longevity of numerous allogenic organ transplants [1]. Its immunosuppressive effect is mostly due to the reduction of interleukin 2 synthesis by T-helper cells, which is required for B cell and cytotoxic T cell proliferation [2,1]. Cyclosporine therapy, while it became the immunosuppressant of choice in clinical transplantation in the 1980s, can be worsened by a number of side effects, including nephrotoxicity, hepatotoxicity, and hypertension [3]. Nephrotoxicity is the most common and clinically significant of all the recognised side effects, and it may eventually limit the use of cyclosporine [4]. Reduced glomerular filtration rate and proximal tubular damage are common side effects of cyclosporine-induced nephrotoxicity [3,5]. Toxic tubulopathy indicated by nonspecific vacuolization, enlargement of the endoplasmic reticulum and mitochondria in tubular epithelial cells, and capillary congestion and arteriopathy are among the morphological alterations [6]. Cyclosporine therapy caused endothelial damage, capillary thrombosis, and glomerular infarction in an animal model, akin to a generalised Schwartzman reaction [7]. Based on this and other findings, some researchers believe that cyclosporine suppresses the manufacture of a prostacyclin-stimulating factor in the kidney, resulting in decreased prostacyclin production by endothelial cells [7]. Prostacyclin is a potent antagonist of thromboxane-mediated platelet aggregation and subsequent thrombosis; it also plays an important role in renal autoregulation by acting as a physiologic antagonist to the vasoconstrictive effect of angiotensin II [8]. Hence, decreased prostacyclin production may partly explain the hypertension and accelerated renal arteriolar lesions initiated

by cyclosporine. It appears that endothelial injury is an important feature of cyclosporine induced nephrotoxicity, the mechanism of cyclosporine-induced nephrotoxicity clearly requires further elucidation. Cyclosporine-A has played an important role in the development of organ transplants, its therapeutic use has been severely limited due to the nephrotoxicity of CsA, a common and serious side effect [9]. In experimental animals, Cyclosporine A has been reported to cause acute renal vasoconstriction, followed by a decrease in glomerular filtration rate and renal blood flow. A down regulation of calbindin D 28 kDa, a vitamin D-dependent calcium binding protein, has been reported to be a critical factor for the renal side-effects of CsA [10].

The kidney is a critical part of the metabolic machinery, saddled with central role of homeostasis as well as excretion of metabolic waste. Over production of intermediate toxic radicals can disturb the innate antioxidant guard mechanism, leading to several pathological disorders of this organ [11,12]. Furthermore, overwhelming levels of free radicals may cause the depletion of thiols and result in lipid peroxidation, leading to cell membrane damage and hepatic injury [13,14]. End stage renal disease is best managed by kidney transplant. This increases the rate of survival when compared to dialysis. Prevention of acute or chronic rejection necessitates the use of immunosuppressants. However, nephrotoxicity, hepatotoxicity, cardiovascular disease, post transplantation diabetes mellitus, chronic graft dysfunction and dyslipidemia may manifest as complications of immune-suppressive therapy [15].

With its vast source of bioactive components and therapeutic relevance, Ginkgo biloba supplement is one of the most astounding herbal medications

considered by scientists all over the world. It contains a variety of bioactive chemicals, including terpenoids (e.g., ginkgolides, bilobalides), flavonoids (e.g., kaempferol, quercetin, isorhamnetin), biflavonoids (e.g., sciadopitysin, ginkgetin, isoginkgetin), organic acids (e.g., ginkgolic acid), and organic acids (The standard extract of *Ginkgo biloba* leaves (EGb 761) is widely used for the treatment of neurological and cardiovascular problems [16,17], and it is considered one of the most commonly used therapeutic plants [18,19]. *Ginkgo biloba* supplement (GBS) exhibits promising biological activities against neurodegenerative and vascular disorders [20,21]. Besides, flavonoids possess the ability to attenuate the majority of enzymes integrated into inflammatory cascades. Flavonoids also exert beneficial effects in cardiovascular diseases, possibly by inhibiting coagulation, thrombus formation, and platelet aggregation [22]. Terpenoids have been shown to suppress the nuclear factor- κ B signaling in inflammation and cancer pathogenesis [23]. *Ginkgo biloba* supplement has been reported to show nephroprotective effect against methotrexate [24], gentamicin, and cisplatin-Induced renal damage and nephrotoxicity [25,26]. It enhanced blood flow [27], and showed protective effect against doxorubicin-Induced cardiotoxicity [28]. It shows protective action against oxidative stress and nephrotoxicity induced by vancomycin [29].

The purpose of the present study would be to investigate the protective effect of *Ginkgo biloba* supplement on cyclosporine-induced renal toxicity in male Wistar rats.

2. MATERIALS AND METHODS

2.1 Animals

Twenty (20) male Wistar rats were used for this experiment with their weight ranging between 120g to 150g. The animals were procured from the Animal House; University of Port-Harcourt and was transported to Animal House, PAMO University of Medical Science, Port-Harcourt, Rivers State Nigeria and fed on standard pelleted rat chow and drinking tap water *ad libitum*. The animals were kept and maintained under convectional laboratory conditions of temperature of 20°C.

2.2 Chemicals

Cyclosporine-A (CsA) was purchased from Sigma (St. Louis, MO, USA), *Ginkgo*

biloba supplement was gotten from Mason Natural chemicals (China). Creatinine, Urea and Total Protein-Randox kits for biochemical assays were purchased from Randox Laboratories Limited, Crumlin, United Kingdom.

2.3 Biochemical Assay

The amounts of creatinine, urea, and total protein in the serum for renal function were measured using a Randox test kit according to Reitman and Frankel's procedure [30].

2.4 Histology

The kidney was fixed in 10% phosphate-buffered formalin, dehydrated in increasing concentration of ethanol, cleared with xylene, embedded in paraffin, sectioned and stained following circumspectly the method of Baker 1945. Two micrometer (2 μ m) sections was prepared from the kidney paraffin blocks and stained with hematoxylin and eosin (H&E). The stained slides were photographed at 400x magnification with a light microscope, and the photomicrographs were analysed for morphological changes.

2.5 Experimental Design

The animals were acclimatized for two weeks under convectional laboratory conditions of temperature of 20°C and they were randomly selected into four groups containing 5 rats as follows; group 1 served as normal control and was treated with water, group 2 was treated with cyclosporine-A at 25mg/kg according to the studies of [31], group 3 was treated with *Ginkgo biloba* supplement (GBS) (50mg/kg), the dosage was according to a previous study by [32] and group 4 was treated with cyclosporine-A + GBS simultaneously. All treatments were done through intraperitoneal route. The experiment was terminated in 15 days, animals were anaesthetized with ketamine (70mg/Kg), blood sample were collected through cardiac puncture into EDTA bottle and thereafter were centrifuged and plasma was separated for biochemical assay. The kidney was harvested and preserved in 10% phosphate-buffered formalin for histological examination.

2.6 Statistical Analysis

Data was expressed as Means \pm Standard Error of Mean. All data were subjected to one-

way analysis of variance (ANOVA) and comparison within groups was performed with *Post hoc Newman-Keulstest* with Graph Pad prism 7.0 (San Diego, CA, USA). P-value of less than 0.05% was considered significant.

3. RESULTS

3.1 Right Kidney

There was no significant ($p>0.05$) difference in CsA (0.25 ± 0.01), GBS (0.33 ± 0.02) CsA+ GBS (0.28 ± 0.03) when compared with control (0.29 ± 0.02) group as shown in Fig. 1.

3.2 Left Kidney

There was no significant ($p>0.05$) difference in CsA (0.28 ± 0.01), GBS (0.33 ± 0.02) and CsA +GBS (0.28 ± 0.02) when compared with control (0.3 ± 0.02) group as shown in Fig. 2.

3.3 Total Protein (TP)

There was a significant ($p<0.05$) decrease in total protein concentration in CsA group (26.7 ± 0.85) when compared with control group (41.7 ± 5.95). Following GBS treatment, GBS (74.5 ± 3.4) and CsA + GBS (81.7 ± 3.66) significantly ($p<0.05$) increased when compared with CsA group as shown in Fig. 4.

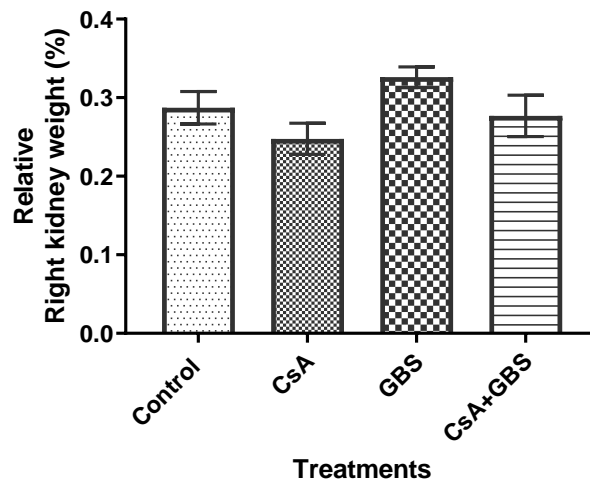


Fig. 1. Weight of right kidney

Values are expressed as mean + SEM (n=5).
CsA = Cyclosporine-A and GBS= Ginkgo biloba Supplement

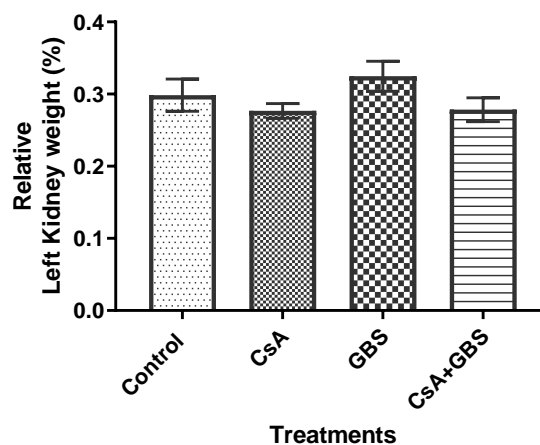


Fig. 2. Weight of left kidney

Values are expressed as mean + SEM (n=5).
CsA = Cyclosporine-A and GBS= Ginkgo biloba Supplement

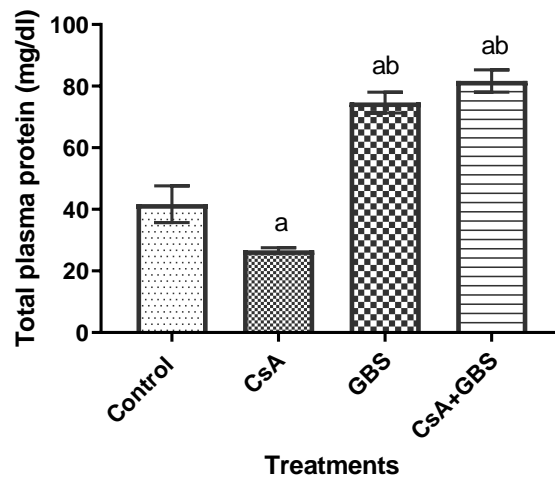


Fig. 3. Total protein

Values are expressed as mean + SEM (n=5). ^ap<0.05 was significant when compared with control while ^bp<0.05 was significant when compared with CsA treated group. CsA = Cyclosporine-A and GBS= Ginkgo biloba Supplement

3.4 Creatinine

Creatinine significantly ($p<0.05$) increased in CsA group (276 ± 7.79) when compared with control (154 ± 8.57). However, GBS (169 ± 7.19) and CsA + GBS (207 ± 6.57) were significantly ($p<0.05$) reduced when compared with CsA group as shown in Fig. 5.

3.5 Urea

Fig. 6 shows that plasma concentration of urea in CsA group (41.6 ± 1.89) increased significantly ($p<0.05$) when compared to control (20 ± 1.44). However, GBS (28.1 ± 2.48) and CsA +GBS (34.3 ± 2.12) decreased significantly ($p<0.05$) when compared with control and CsA group.

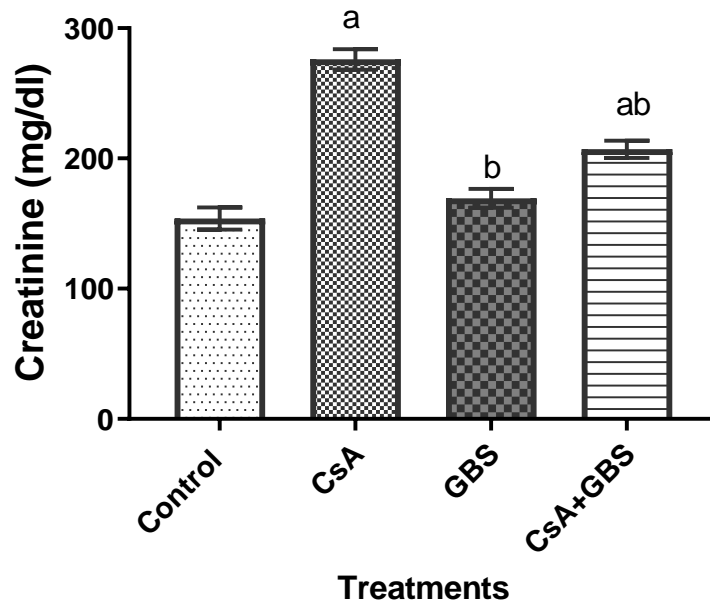


Fig. 4. Creatinine level

Values are expressed as mean + SEM (n=5). ^ap<0.05 was significant when compared with control while ^bp<0.05 was significant when compared with CsA treated group. CsA = Cyclosporine-A and GBS= Ginkgo biloba Supplement

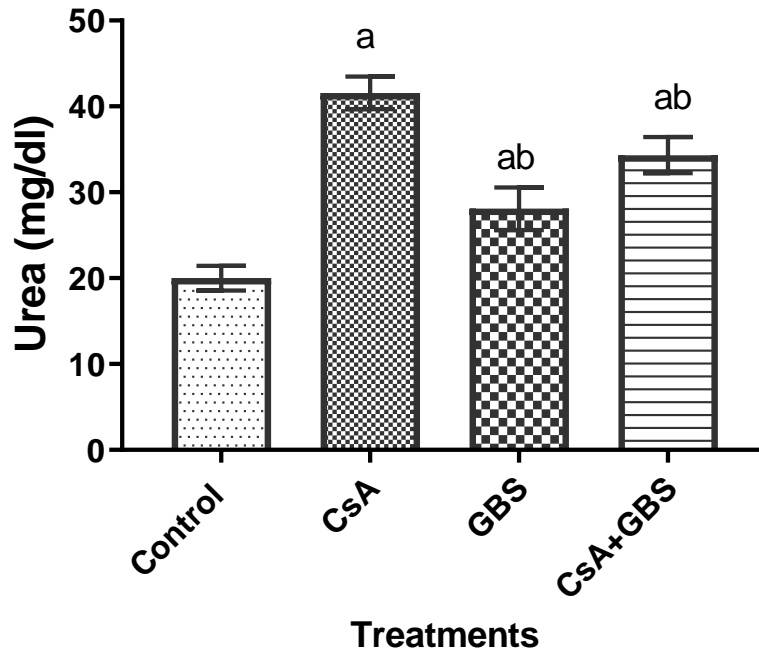


Fig. 5. Urea level

Values are expressed as mean + SEM (n=5). ^ap<0.05 was significant when compared with control while ^bp<0.05 was significant when compared with CsA treated group. CsA = Cyclosporine-A and GBS= Ginkgo biloba Supplement

3.6 Ginkgo biloba Supplement Protects Against Cyclosporine-A Induced Kidney Toxicity in Male Wistar Rats

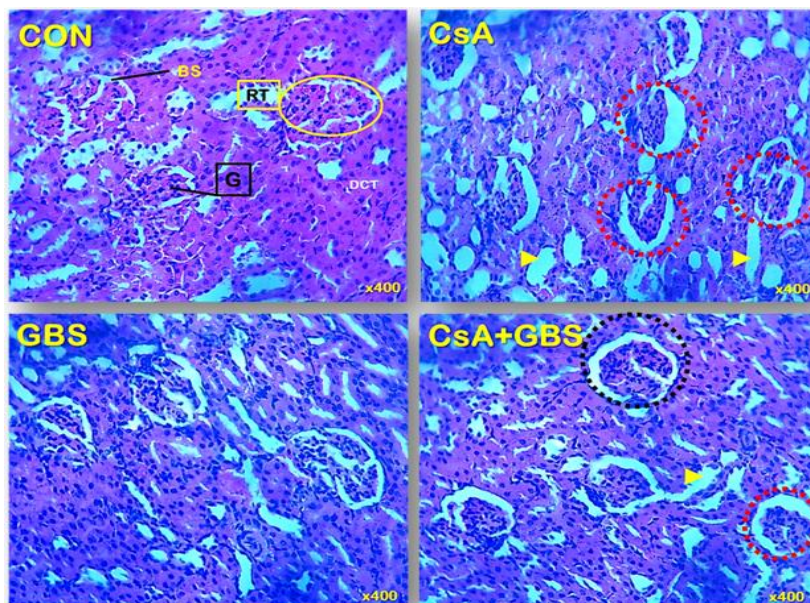


Fig. 6. Histological presentation of the kidney (H&Ex400) showing the cortex.

Glomerulus (G), Renal tubules (RT), Distal convoluted tubules (DCT), Bowman's space (BS), Proximal and distal tubular necrosis (arrow head).

Mild dilatation and atrophy of the glomerular tubules (dotted circle),
CsA = Cyclosporine-A and GBS= Ginkgo biloba Supplement

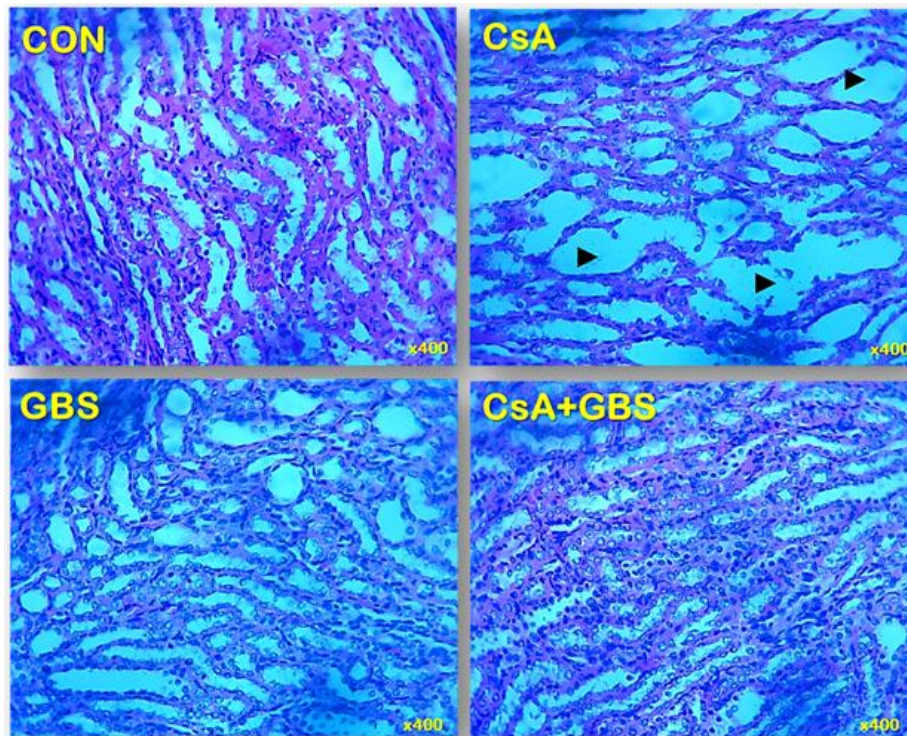


Fig. 7. Histological presentation of the kidney (H&Ex400) showing the medulla.
Mild dilatation and atrophy of the medulla tubules (arrow head)

4. DISCUSSION

Cyclosporine-A (CsA) is an immunosuppressive drug commonly used to treat autoimmune problems after organ transplantation [1]. Cyclosporine toxicity has been observed in various organs, including the kidney, brain, and heart [3]. The kidneys are a vital component of the metabolic machinery, playing a key role in homeostasis and metabolic waste excretion. Over production of intermediate toxic radicals can disturb the innate antioxidant guard mechanism, leading to several pathological disorders of these organs [11]. The use of plant supplements or herbal remedies; the treatment of several diseases and the ethno medicinal efficacy of plant supplements in several kidney malfunctions have been reported in literatures [32]. In this study, the weight of the kidney was not affected this might have been as a result of the duration of the study. In Cyclosporine intoxicated animals, observation was made of a significant increase in serum urea and creatinine levels, this was also reported in previous studies [33,34]. Increased protein breakdown is caused by oxidative stress, which boosts ammonia levels and, as a result, serum urea concentrations [35]. The brush border epithelia of renal cells were broken down by free radicals, rendering the cells

impermeable to urea and creatinine [36]. Due to restricted or no tubular absorption of urea by the renal tubules, the levels of these kidney biomarkers in the blood rise. In the current study, *Ginkgo biloba* supplement significantly lowered urea and creatinine levels. *Ginkgo biloba*'s renal protective effect in cyclosporine poisoning may be related to its antioxidant capacity, counteracting the oxidative attacks that occur in the kidney as a result of cyclosporine-induced toxicity. Histological examination showed that *Ginkgo biloba* supplementation repaired tissue structural abnormalities caused by cyclosporine treatment. Cyclosporine induces oxidative stress in the kidneys, resulting in pathological changes as previously established by [34] and [37]. According to studies on cyclosporine transit in the kidney, it is absorbed by proximal tubular cells [38]. High levels of cyclosporine can also damage the renal tubules, causing glomerular and tubular atrophy and accidental tubular epithelial coagulative necrosis [39,40]. *Ginkgo biloba* supplementation has been shown to protect histological integrity in injured renal tissue with parenchymal necrosis, tubular dilatations, and hyperaemic situations [41], which is consistent with the findings of histological studies. The histological type of kidney injury was revealed to be greatly reduced after *Ginkgo*

biloba supplement consumption. Findings in this study matched those of [37], who discovered similar effects from ginger therapy. The histological studies also showed that treatment with *Ginkgo biloba* supplements resulted in the restoration of kidney structure [42].

5. CONCLUSION

According to the findings of this study, *Ginkgo biloba* supplements significantly reduced serum urea and creatinine levels in response to cyclosporine increases. As a result of biochemical assay, *Ginkgo biloba* appeared to play an important role in protecting kidneys from oxidative damage and changes in tissue structure.

DISCLAIMER

The products used for this research are commonly and predominantly use products in our area of research and country. There is absolutely no conflict of interest between the authors and producers of the products because we do not intend to use these products as an avenue for any litigation but for the advancement of knowledge. Also, the research was not funded by the producing company rather it was funded by personal efforts of the authors.

CONSENT

It is not applicable.

ETHICAL APPROVAL

This study was approved and the protocol adhered to the University Ethical Committee on Animal Experimentation (PUMS-AREC/043) guidelines, which are in accordance with the 'Principle of Laboratory Animal Care (NIH Publication N0.85-23).

COMPETING INTERESTS

Authors have declared that no competing interests exist.

REFERENCES

1. Kahan BD. Cyclosporine: A powerful addition to the immunosuppressive armamentarium. *American Journal of Kidney Diseases*. 1984;3(6):444-455.
2. Cohen DJ, Loertscher R, Rubin MF, Tilney NL, Carpenter CB, Strom TB. Cyclosporine: A new immunosuppressive agent for organ transplantation. *Annals of Internal Medicine*. 1984;101(5):667-682.
3. Shulman H, Striker G, Kennedy M, Storb R, Thomas ED. Nephrotoxicity of cyclosporine A after allogeneic marrow transplantation. Glomerular thrombosis and tubular injury. *New English Journal of Medicine*. 1981;305(23):1392-1395.
4. Canadian Multicentre Transplant Study Group. A randomized clinical trial of cyclosporine in cadaveric renal transplantation. *New England Journal of Medicine*. 1983;309(14):809-815.
5. Myers BD, Ross J, Newton L, Luetscher J, Perlroth M. Cyclosporine associated chronic nephropathy. *New England Journal of Medicine*. 1984;311(11):699-705.
6. Mihatsch MJ, Thiel G, Basler B, Ryffel B, Landmann J, Von Overbeck J, Zollinger HU. Morphological patterns in cyclosporine-treated renal transplant recipients. *Transplant Proc*. 1985;17(l):101-116.
7. Nield GH, Ivory K, Williams DG. Glomerular thrombi and infarction in rabbits with serum sickness following cyclosporine therapy. *Transplantation Proceedings*. 1983;15(4).
8. Weber PC, Larsson C, Anggard E, Hamberger M, Corey EJ, Nicolaou KC, Samuels B. Stimulation of renin release from rabbit renal cortex by arachidonic acid and prostaglandins. *Circulation Research*. 1976;39(6):868-874.
9. Fahr A. Cyclosporine clinical pharmacokinetics. *Clinical Pharmacokinetics*. 1993;24(6):472-495.
10. Steiner S, Aicher L, Raymackers J, Meheus L, Esquer-Blasco R, Anderson NL, Cordier A. Cyclosporine a decreases the protein level of the calcium-binding protein calbindin-D 28kDa in rat kidney. *Biochemical Pharmacology*. 1996; 51(3):253-258.
11. Cichoż-Lach H, Michalak A. Oxidative stress as a crucial factor in liver diseases. *World Journal of Gastroenterology*. 2014; 20(25):082.
12. Dikici I, Mehmetoglu I, Dikici N, Bitirgen M, Kurban S. Investigation of oxidative stress and some antioxidants in patients with acute and chronic viral hepatitis B and the effect of interferon- α treatment. *Clinical Biochemistry*. 2005;38(12):1141-1144.
13. Abbès S, Ben Salah-Abbès J, Jebali R, Ben Younes R, Oueslati R. Interaction of aflatoxinB1 and fumonisin B1 in mice

- causes immunotoxicity and oxidative stress: Possible protective role using lactic acid bacteria. *Journal Immunotoxicology*. 2016;13(1):46–54.
14. Farinati F, Cardin R, De Maria N, Della Libera G, Marafin C, Lecis E, Burra P, Floreani A, Cecchetto A, Naccarato R. Iron storage, lipid peroxidation and glutathione turnover in chronic anti-HCV positive hepatitis. *Journal of Hepatology*. 1995; 22(4):449–456.
 15. Ivandic E, Basic-Jukic N. Liver damage caused by atorvastatin and cyclosporine in patients with renal transplant. *Acta Med Croatica*. 2014;68(2):175-8.
 16. Singh B, Kaur P, Singh RD, Ahuja PS. Biology and chemistry of Ginkgo biloba. *Fitoterapia*. 2008;79(6):401–418.
 17. Vellas B, Coley N, Ousset PJ, Berrut G, Dartigues JF, Dubois B, Grandjean H, Pasquier F, Piette F, Robert P, Touchon J. Long-term use of standardized Ginkgo biloba extract for the prevention of Alzheimer's disease (GuidAge): A randomized placebo-controlled trial. *Lancet Neurol*. 2012;11(10):851–859.
 18. Van Beek TA, Montoro P. Chemical analysis and quality control of Ginkgo biloba leaves, extracts, and phytopharmaceuticals. *J. Chromatogr. A*. 2009;1216:2002–2032.
 19. Nakanishi K. Terpenylactones from Ginkgo biloba: From ancient times to the 21st century. *Bioorg. Med. Chem*. 2005; 13(17):4987–5000.
 20. Cicero AFG, Fogacci F, Banach M. Botanicals and phytochemicals active on cognitive decline: The clinical evidence. *Pharmacol. Res*. 2017;130:204–212.
 21. Sung JH, Shah FA, Cho EH, Gim SA. Ginkgo biloba extract (EGb 761) prevents the ischemic brain injury-induced decrease in parvalbumin expression. *Lab. Anim. Res*. 2012;28:77–82.
 22. Jiang F, Dusting GJ. Natural phenolic compounds as cardiovascular therapeutics: potential role of their anti-inflammatory effects. *Curr.Vasc. Pharmacol*. 2003;1:135–156.
 23. Salminen A, Lehtonen M, Suuronen T, Kaarniranta K, Huuskonen J. Terpenoids: natural inhibitors of NF-kappaB signaling with anti-inflammatory and anticancer potential. *Cell Mol. Life Sci*. 2008;65:2979–2999.
 24. Tousson E, Atteya Z, El-Atrash E, Jeweely OI. Abrogation by Ginkgo biloba leaf extract on hepatic and renal toxicity induced by methotrexate in rats. *Journal of Cancer Research and Treatment*. 2014;2(3):44-51
 25. Öztürk G, Anlar Ö, Erdoğan E, Kösem M, Özbek H, Türker A. The effect of Ginkgo extracts EGb761 in cisplatin-induced peripheral neuropathy in mice. *Toxicology and applied Pharmacology*. 2004; 196(1):169-75.
 26. Gulec M, Iraz M, Yilmaz HR, Ozyurt H, Temel I. The effects of Ginkgo biloba extract on tissue adenosine deaminase, xanthineoxidase, myeloperoxidase, malondialdehyde and nitric oxide in cisplatin-induced nephrotoxicity. *Toxicology and Industrial Health*. 2006; 22(3):125-30
 27. Dubey BJ, Shankar PR, Upadhyaya D, Deshpande VY. Ginkgo biloba – An appraisal. *Kathmandu University medical journal (KUMJ)*. 2004;2(3):225-9.
 28. Naidu MU, Kumar KV, Mohan IK, Sundaram C, Singh S. Protective effect of Ginkgo biloba extract against doxorubicin-induced cardiotoxicity in mice. *Indian J. Exp Biol*. 2002;40(8):894-900
 29. Celik I, Chihangiroglu M, Ilhan N, Akpolat N, Akbulut HH. Protective effects of different antioxidants and amrinone on vancomycin-induced nephrotoxicity. *Basic & Clinical Pharmacology & Toxicology*. 2005;97(5):325-32.
 30. Adeyemi O, Ajayi JO, Olajuyin AM, Oloyede OB, Oladiji AT, Oluba OM, Adebayo EA. Toxicological evaluation of the effect of water contaminated with lead, phenol and benzene on liver, kidney and colon of Albino rats. *Food Chemistry and Toxicology*. 2009;47(4):885-887.
 31. Sagiroglu T, Kanter M, Yagei MA, Sezer A, Erboga M. Protective effect of curcumin on cyclosporine A induced endothelial dysfunction, antioxidant capacity and oxidative damage. *Toxicology and Industrial Health*. 2012;1 – 12.
 32. Asiwe JN, Kolawole TA, Anachuna KK, Ebuwa EI, Nwoguzue BC, Eruotor H, Igbokwe V. Cabbage juice protect against lead-induced liver and kidney damage in male Wistar rat. *Biomarkers*. 2022;1-8.
 33. Reitman et al. A colorimetric method for the determination of serum glutamic oxalacetic and glutamic pyruvic transaminases. *American Journal of Clinical Pathology*. 1957;28:56

34. Offor SJ, et al. Lead induced hepato-renal damage in male albino rats and effects of activated charcoal. *Frontiers in pharmacology*. 2017;8:107.
35. Renugadevi J, Prabu SM. Cadmium-Induced hepatotoxicity in rats and the protective effect of naringenin. *Exp Toxicol Pathol*. 2010;62(2):171-181.
36. Yuan G, Dai S, Yin Z. Sub-chronic lead and cadmium co-induce apoptosis protein expression in liver and kidney of rats. *Int J Clin Exp Pathol*. 2014;7(6):2905.
37. Reddy YA, et al. Ameliorating activity of ginger (*Zingiber officinale*) extract against lead induced renal toxicity in male rats. *Journal of food science and technology*. 2014;51(5):908-914
38. Vander AJ, Mouw DR, Cox J, Johnson B. Lead transport by renal slices and its inhibition by tin. *American Journal of Renal Physiology*. 1979;236(4): F373-F378.
39. Ekong EB, Jaar BG, Weaver VM. Lead-related nephrotoxicity: A review of the epidemiologic evidence. *Kidney Int*. 2006; 70(12):2074-2084.
40. Laamech J, El-Hilaly J, Fetoui H, Chtourou Y, Gouitaa H, Tahraoui A, Lyoussi B. *Berberis vulgaris* L. effects on oxidative stress and liver injury in lead-intoxicated mice. *Journal of Complimentary and Integrative Medicine*. 2017;14(1):1-14.
41. Kademir FM, Yildirim S, Caglayan C, Kucukler S, Eser G. Protective effects of zingerone on cisplatin-induced nephrotoxicity in female rats. *Environ Sci. Pollut. Res*. 2019;26(22):22562-22574.
42. Chan PC, Xia Q, Fu PP. Ginkgo biloba leave extract: biological, medicinal and toxicological effects. *J Environ Sci Health C Environ CarcinogEcotoxicol Rev*. 2007; 25:211-244.

© 2022 Nwokoma et al.; This is an Open Access article distributed under the terms of the Creative Commons Attribution License (<http://creativecommons.org/licenses/by/4.0>), which permits unrestricted use, distribution, and reproduction in any medium, provided the original work is properly cited.

Peer-review history:

The peer review history for this paper can be accessed here:
<https://www.sdiarticle5.com/review-history/85049>