

Facial Neurocutaneous Markers and their Clinical Profile- A Case Series

BIBEKANANDA MUKHERJEE¹, BARNALI DAS², JOYDEEP DAS³

ABSTRACT

Cutaneous birth marks are heterogeneous group of congenital skin lesions with a high diagnostic value. A good clinician by looking at the skin, eye and face can diagnose conditions like Neurofibromatosis type 1 (NF1), Tuberous Sclerosis Complex (TSC), Ataxia-telangiectasia, Von Hippel-Lindau disease, Sturge-Weber Syndrome (SWS) and others. The author reports in the present case series, six cases presenting with one or more of the following seven different types of facial neurocutaneous markers like Café-au-lait Macules (CALM), neurofibromas, facial angiofibromas, forehead plaque, hypomelanotic macules (ash-leaf) on the trunk and extremities, capillary malformation in the face (port-wine stain) and ocular telangiectasia. Using these cutaneous markers as red alerts, the authors did a focused clinical examination, ophthalmic and auditory evaluation, neuroimaging, renal and cardiac evaluation to come to a diagnosis. This helped us in detecting clinical syndromes like NF1, TSC, SWS and unveiled the hidden morbidities like hypertension, intracranial tumours, intracardiac rhabdomyoma, glaucoma and others ocular abnormalities. The present case series emphasises on the need for all Paediatrician and Ophthalmologist, to develop a clinical eye to identify neurocutaneous markers in children, who may arrive at their clinic with various problems for early diagnosis and treatment of various neurocutaneous syndrome and their co-morbidities.

Keywords: Ash-leaf Macule, Café-au-lait spot, Haemangioma, Neurocutaneous markers, Telangiectasia

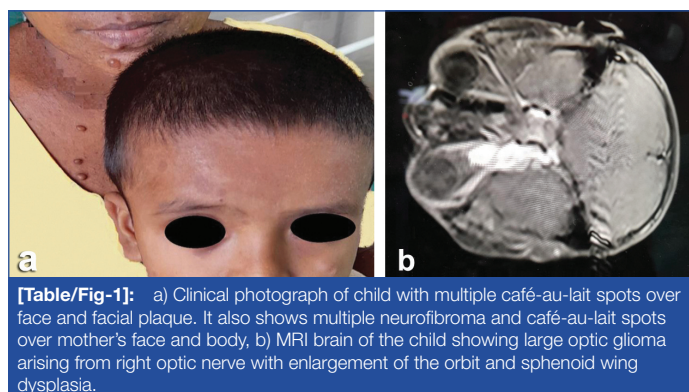
INTRODUCTION

The embryogenesis of the central nervous system is initiated from the ectoderm. The ectoderm is further sub-specialised as the surface ectoderm, which differentiates into the epidermis, nails, and hair and the neural ectoderm, which gives rise to the neural tube and neural crest, which subsequently give rise to the brain, spinal cord, and peripheral nerves [1]. The neurocutaneous syndromes include a heterogeneous group of disorders characterised by abnormalities of both the integument and central nervous system of variable severity. Many of the disorders are inherited and believed to arise from a defect in differentiation of the primitive ectoderm (nervous system, eyeball, retina, and skin) [2]. The various cutaneous markers which are present since birth or appearing after birth like vascular malformation, nevus, café-au-lait spots, neurofibroma, ash-leaf macule, ocular telangiectasia and others are very important clinical pointers to an underlying abnormalities in other major organs like brain, spinal cord, eye, kidneys, heart [3-5].

CASE SERIES

Case 1

A five-year-old male child reported with progressive headache and difficulty in vision without any seizures. The visual acuity of right eye was reduced for both distant and near vision. On examination there were 11 CALM over face, trunk and limbs varying from 7x4 mm to 11x5 mm sizes. He had multiple neurofibromas over hands and feet. He also had a facial plaque [Table/Fig-1a]. Blood pressure was found to be more than 95th centile according to age, height and sex and was treated with anti-hypertensive medication. His mother was found to have multiple neurofibromas all over the body and his elder sister was found to have few CALM. The slit lamp examination of eye showed multiple iris lisch nodules in both the eyes. Magnetic Resonance Imaging (MRI) brain was done which showed large optic glioma arising from right optic nerve with enlargement of the orbit and sphenoid wing dysplasia [Table/Fig-1b]. The diagnosis of NF1 was established due to the presence of CALM (six or more CALM >5 mm in greatest diameter in prepubertal individuals),



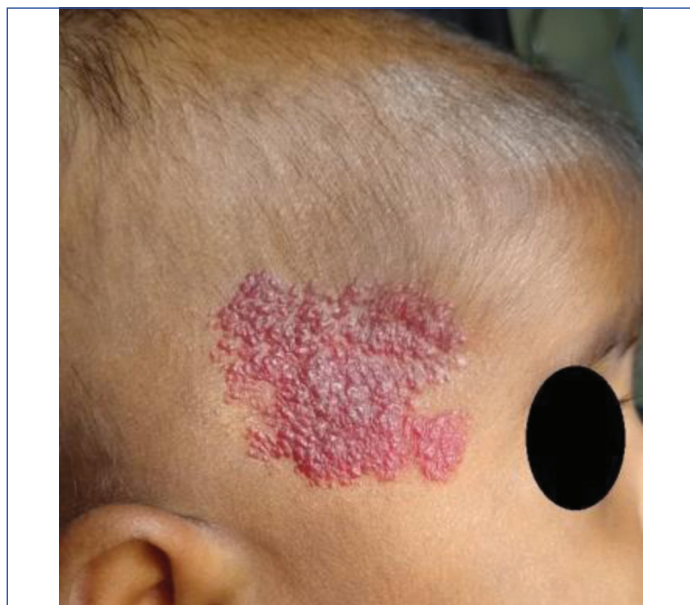[Table/Fig-1]: a) Clinical photograph of child with multiple café-au-lait spots over face and facial plaque. It also shows multiple neurofibroma and café-au-lait spots over mother's face and body, b) MRI brain of the child showing large optic glioma arising from right optic nerve with enlargement of the orbit and sphenoid wing dysplasia.

neurofibroma, iris Lisch nodules, positive family history and optic glioma and sphenoid wing dysplasia [6]. The child was referred to neurosurgeon. His renal and adrenal ultrasound and renal artery doppler were normal. Echocardiography was also found to be normal. Hearing assessment was also normal. The child was started on antihypertensive medication- amlodipine and was immediately referred to neurosurgeon and eye surgeon for surgical management of optic glioma.

Case 2

An eight-month-old female baby reported with a superficial lesion over right temple with a deep red, pebbly surfaced lesion which was having irregular margin measuring about 10x5 cm. The lesion was blanching on pressure and consistent with strawberry haemangioma [Table/Fig-2]. Mother also noticed watering from right eye and child avoiding bright light. No other skin lesions were found. The child had achieved normal growth and development for age. Based on the erythematous progressively enlarging large skin lesion over right ophthalmic dermatome (V1) of Trigeminal nerve and its clinical course, possibility of SWS was high [7,8]. Ophthalmic examination revealed increased Intraocular Pressure (IOP) on right eye (IOP 22 mmHg in right eye vs 12 mmHg in left eye) and choroidal vascular malformation. Anti-glaucoma medications were started with plan for surgical intervention in follow-up. MRI brain was normal. Ultrasound

abdomen was done which revealed no haemangioma, elsewhere. Oral propranolol was started at a dose of 1 mg/kg/day and skin lesion significantly regressed in size after three months. The child is currently under ophthalmological follow-up.



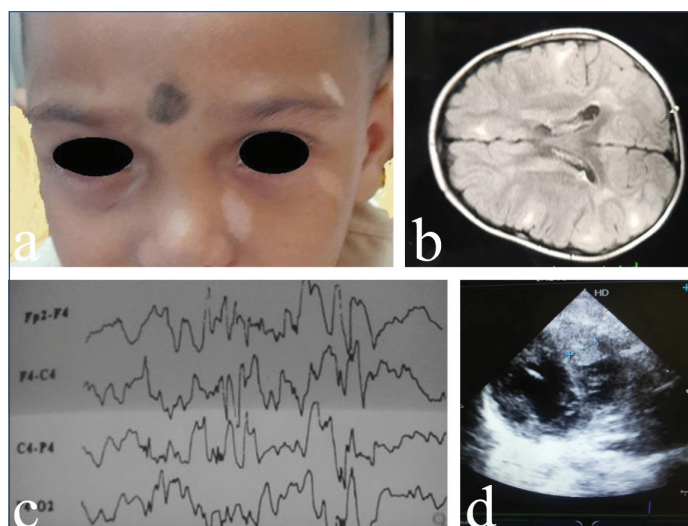
[Table/Fig-2]: Clinical photograph of child with strawberry haemangioma over right ophthalmic dermatome (V1) of trigeminal nerve with raised Intraocular Pressure (IOP) of right eye.

Case 3

A 4-year-old male child reported with status epilepticus, which was controlled with multiple antiepileptic medications. There was no previous history of seizures apart from autistic behaviour. The child had uneventful perinatal history and had achieved normal developmental milestones. On examination of face three well-defined areas of hypopigmentation without any superficial scaling measuring approximately 1.5 cm (maximum in longitudinal axis), was found suggestive of ash-leaf macule. Wood's lamp examination did not reveal any fluorescence. He also had five ash-leaf macules measuring 1.5 to 2 cm in longitudinal axis on the trunk. Neurological examination was normal. Blood pressure was normal for age. On fundoscopy, few tiny white depigmented patches were found in the left eye (ocular ash-leaf). Visual acuity test was normal in both eyes. Magnetic Resonance Imaging (MRI) brain showed multiple subependymal nodules and cortical tuber [Table/Fig-3b]. Electroencephalography (EEG) showed hypsarrhythmia (high-voltage, asynchronous slow waves) [Table/Fig-3c]. Ultrasonography did not reveal any kidney abnormalities. Echocardiography (ECHO) revealed a mass in the left ventricle suggestive to be cardiac rhabdomyoma [Table/Fig-3d]. Child was kept under regular follow-up for cardiac evaluation. Electrocardiogram (ECG) was normal. No other members in the family were found to have similar lesions. The diagnosis of TSC was established by presence of major criteria's like presence of ash-leaf macules more than three with ocular version, cortical tubers and subependymal nodule in MRI [9]. The child was treated with three antiepileptic drugs. This child was initially started on Levetiracetam at the dose of 10 mg/kg/day and gradually increased to 20 mg/kg/day and Clobazam at the dose of 0.5 mg/kg/day. After neuroimaging, vigabatrin was advised but parents could not afford due to financial reasons. So, the child was started on prednisolone (4 mg/kg/day for two weeks and gradually tapered over next six weeks) to which the child responded well. He was then continued on Levetiracetam and clobazam. Seizures are well-controlled now and are under neurological follow-up.

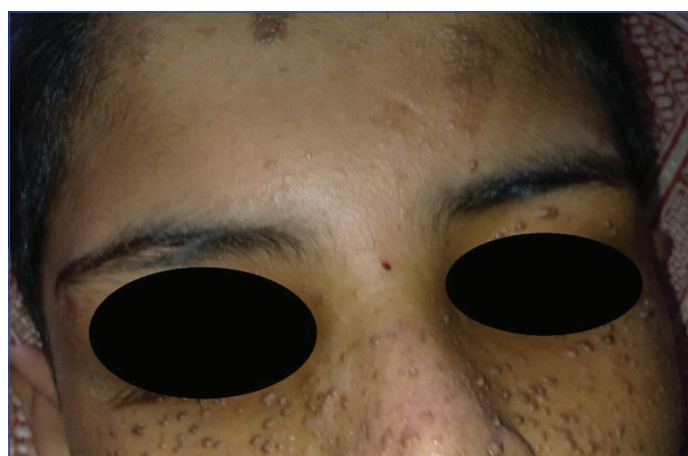Case 4

A 15-year-old female reported with global developmental delay and refractory seizures on multiple antiepileptic drugs. Examination



[Table/Fig-3]: a) Clinical picture of four-year-old male child with three hypopigmented spots over face, b) MRI brain of Case 3 child showing multiple subependymal nodule and cortical tubers, c) Electroencephalogram (EEG) of Case 3 showing hypsarrhythmia (high-voltage, asynchronous slow waves), d) Echocardiogram (ECHO) of Case 3 showing intraventricular rhabdomyoma.

of face showed multiple angiofibromas suggestive of adenoma sebaceum sparing the forehead and a forehead plaque [Table/Fig-4]. In the present case cutaneous ash-leaf macule or any other skin marker was not detected on Wood's lamp examination. Fundoscopy revealed retinal mulberry tumour. Vision was normal. EEG showed hypsarrhythmia. MRI showed multiple subependymal nodules and cortical tubers, however, there was no ventriculomegaly. Echocardiography did not reveal any cardiac mass. Renal ultrasound was also normal. The diagnosis of TSC was established by the presence of five major criteria's like facial angiofibroma (adenoma sebaceum), forehead plaque, MRI showing subependymal nodules with cortical tubers and retinal nodular hamartoma. Seizures were controlled with vigabatrin. The child was started on vigabatrin at the dose of 50 mg/kg/day in two divided doses. Seizures were not well-controlled at this dose, so, the dose had to be escalated to 75 mg/kg/day after two weeks and advised to continue it for six months and be under strict follow-up with paediatric neurologist.

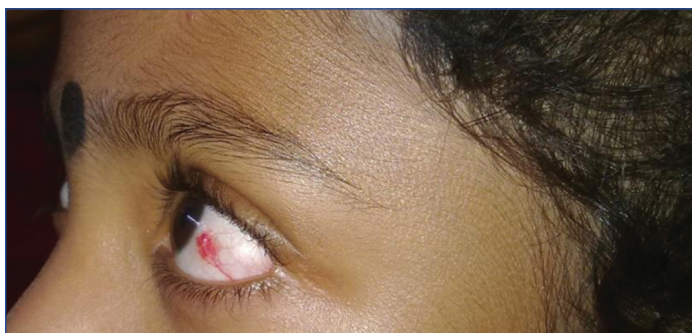

[Table/Fig-4]: Clinical picture of 15-year-old female Case 4 face with multiple angiofibroma (adenoma sebaceum) sparing the forehead with one forehead plaque.

Case 5

A 7-year-old female child reported with history of falls and clumsiness, while walking. She had recurrent history of cough and cold since birth and frequent diarrhoeal episodes. Mother had noticed a change in hand writing and frequent falling of objects from hand for last few months. On examination her weight and height were in the 3rd centiles. She had lost 3 kg weight in last two years. There was no history of contact with tuberculosis and sputum for GeneXpert was negative. She was found to have ataxic gait and poor coordination in hands and she was turning her head (somewhat

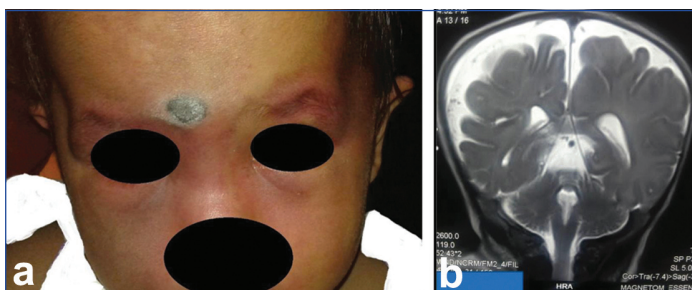more than normal), when she wanted to look at the sides. There was a telangiectatic lesion on left eye which mother noticed for last two years. Ophthalmologists confirmed that there was telangiectasia over sclera with oculomotor apraxia [Table/Fig-5]. Fundal examination was normal. MRI brain showed white matter signal changes in lower brain stem and cervical cord suggestive of degenerative ataxia. The diagnosis of ataxia-telangiectasia was made based on gait ataxia, ocular telangiectasia and MRI findings of white matter changes in brain [6]. Suspecting ataxia-telangiectasia serum Immunoglobulin A (IgA) level and Alpha Fetoprotein (AFP) estimation revealed low serum IgA level and very high AFP levels. So, a diagnosis of Ataxia Telangiectasia was made and genetic test was advised. Parents were counselled and the child was advised to avoid unnecessary exposure to ionising radiation (X-ray, CT scan).



[Table/Fig-5]: Clinical picture of 7-year-old female Case 5 with left eye telangiectasia over sclera.

Case 6

A 9-month-old female child presented with developmental delay and reddish blue discolouration of skin involving right half of face, right hand and right leg. There was also mild hypertrophy of the right leg compared to the left [Table/Fig-6a]. Ophthalmological examination revealed glaucoma in the right eye. MRI of brain showed right cerebral hemiatrophy, hypertrophied choroids plexuses, left parieto-occipital gliosis with marked leptomeningeal enhancement along left parieto-occipital gyri [Table/Fig-6b]. The child was started on antiglaucoma medications and prophylactic anticovulsant. The child was also started on propranolol 1 mg/kg/day. A few months later the child came to emergency with intractable seizures mostly involving left half of body followed by left-sided hemiparesis, but the skin lesions had become fainter and were regressing. In this case the diagnosis of SWS (Type I Roach scale) was made based on the constellation of symptoms and signs of capillary malformation in the face (port-wine stain) and brain abnormalities (leptomeningeal) and glaucoma [4,7]. Parents were counselled regarding the prognosis and kept on follow-up with antiepileptic medications.



[Table/Fig-6]: a) Clinical picture of nine-month-old female Case 6 with reddish-blue discolouration of skin involving right half of face suggestive of port-wine stain present since birth, b) MRI brain of above child Case 6 showing right cerebral hemiatrophy, hypertrophied choroids plexuses, left parieto-occipital gliosis with marked leptomeningeal enhancement along left parieto-occipital gyri.

DISCUSSION

Dermatological examination is a very important clue for diagnosing different diseases of brain, as embryologically both structures arise from same neural crest [1,2]. In the present case series, the varied skin changes found in six children, which were present

since birth or had appeared after birth like vascular malformation, nevus, CALM, neurofibroma, facial plaques, port-wine stain, ash-leaf macule in face, trunk or limbs were pointers to underlying syndromes [Table/Fig-7]. These various cutaneous markers were associated with MRI brain abnormalities in 83% (5 out of 6 cases) against 62-93% reported in other studies [3]. In the present series, 83% of cases (5 out of 6 cases) with cutaneous markers having ophthalmological findings in form of raised IOP, abnormal vasculature, retinal abnormalities supporting the need for detailed ophthalmological evaluation in every child with cutaneous marker (30-70% reported in other studies) was observed [4]. In one case, authors could find a cardiac mass probably rhabdomyoma because it was a case of tuberous sclerosis (50% reported in other cases) [5].

The neurocutaneous syndromes which have been discussed in our case series are NF1, TSC, SWS, ataxia telangiectasia. The diagnosis of these is essentially clinical based on set diagnostic criteria [6-8]. Genetic diagnosis may help to confirm those cases, where one cannot come to definite conclusion based on clinical evidence. All these cases being genetically transmitted, pedigree tracing again plays a very important part of history apart from thorough focused clinical examination. Follow-up of these children involve paediatrician, ophthalmologist, audiologist, cardiologist and neurologist. Genetic counselling plays an important role in these inherited conditions and also, antenatal advices to the mother [10].

The NF1 has an incidence of 1 in 3,000 live births and is caused by autosomal dominant loss-of-function mutations in the NF1 gene [6]. Approximately, 50% are inherited from an affected parent, and the other 50% result from a sporadic gene mutation [11,12]. The condition is clinically diagnosed when any two of the following seven features are present: (a) six or more CALM >5 mm in greatest diameter in prepubertal individuals and > 15 mm in greatest diameter in postpubertal individuals in almost 100% of patients; (b) Axillary oringual freckling; (c) Two or more iris Lisch nodules from only 5% of children younger than three year of age, to 42% among children 3-4 year of age; (d) Two or more neurofibromas; (e) A distinctive osseous lesion such as sphenoid dysplasia (which may cause pulsating exophthalmos) or cortical thinning of long bones with or without pseudoarthrosis (most often the tibia); (f) Optic gliomas are present in approximately 15-20% of individuals with NF1 (g) A first-degree relative with NF1. In Case 1 of the present series, six criteria were fulfilled. One child had hypertension in addition, which in a case of NF1 can be due to renal artery stenosis or phaeochromocytoma [6]. These children in additionally have certain behavioural issues like attention deficit hyperactivity.

In the two cases number 2 and 6 of the present series, SWS Type I (Roach Scale) was diagnosed, as both facial and leptomeningeal angiomas were present with glaucoma. Literatures report that only 20-50 % of children with port-wine stain lesions involving the forehead and upper eyelid have SWS, especially, if it is in the distribution of ophthalmic division of the trigeminal nerve [4]. There may be ipsilateral involvement of the brain too. Seizures occur in 75-80% of SWS cases [4]. Early diagnosis and treatment will reduce neurologic sequelae and prevent blindness [7]. Although port-wine stain has high localising value, up to 30% of cases has leptomeningeal involvement [9,13]. In Case 2, there was isolated facial lesion with glaucoma of ipsilateral eye without any cerebral involvement, but in Case 6 there was cerebral involvement, as well, with seizures and hemiparesis.

There were two cases (Case 3 and 4) of TSC in the present series fulfilling the diagnostic criterias. Case 3 had four major (hypomelanotic macules, cardiac rhabdomyoma, subependymal nodules and cortical tubers) and one minor (retinal achromatic patch) features. Case 4 had five major features (facial angiofibroma, forehead plaque, retinal nodular hamartomas, cortical dysplasias

Case	Facial marker	MRI brain	Eye	Kidney	Bone	Cardiac	Hearing and other
Case 1 5-year-old male neurofibromatosis 1 (NF1)	Multiple café-au-lait macules, iris Lisch nodule and facial plaque, Neurofibroma (hand and feet)	Large optic glioma (right optic nerve) sphenoid wing dysplasia	Decreased Visual Acuity, Lisch nodule, optic Glioma	Normal	Sphenoid wing dysplasia	ECHO normal, Hypertension	Hearing normal, Mother and sister having café-au-lait macules
Case 2 8-month-old Female Sturge Weber Syndrome (SWS)	Strawberry haemangioma	Normal	Raised Right eye Intra Ocular pressure, left eye-choroidal vascular malformation	Normal in USG	Normal	Normal	Hearing normal, no haemangioma in other organs
Case 3 4-year-old male Tuberous Sclerosis Complex(TSC)	Ash-leaf macule	Subependymal nodule and cortical tuber	Retinal Achromatic patch, vision normal	Normal	Normal	ECHO -Rhabdomyoma, Normal Blood pressure	Hearing normal, epilepsy, Autistic behaviour, normal. EEG hypsarhythmia
Case 4 15-year-old female Tuberous Sclerosis Complex (TSC)	Angiofibroma (adenoma sebaceum) and facial plaque	Multiple subependymal nodules and cortical tubers	Retinal mulberry tumour	Normal in USG	Normal	Normal	Global developmental delay, EEG -hypsarhythmia, hearing normal
Case 5 7-year-old female ataxia telangiectasia	Left ocular telangiectasia	White matter signal changes in lower brain stem and cervical cord	Left eye telangiectasia, ocular apraxia	Normal	Normal	Normal	Hearing normal, ataxia, recurrent upper and lower respiratory infections, clumsiness in gait, low serum IgA, serum AFP raised
Case 6 9-month-old Female Sturge-Weber Syndrome (SWS)	Port-wine stain (right sided)	Leptomeningeal enhancement, cerebral atrophy	Glaucoma (Rt)	Normal	Normal	Normal	Global developmental delay, hearing normal, right leg hypertrophy, seizures, left hemiparesis

[Table/Fig-7]: Comparative descriptive clinical findings of six cases of neurocutaneous syndromes.

like cortical tubers and subependymal nodules). Presence of two major features or one major feature, plus two or more minor features is diagnostic of TSC [14]. Forehead plaque, mostly present at birth and detectable early in life is a good cutaneous marker for prediction of ipsilateral intracranial abnormalities [6]. Similarly facial ash-leaf macules in face and other areas of body have associated central nervous system, kidney diseases and other abnormalities [6]. TSC may have a varied spectrum of presentation. It may present to a paediatrician with refractory seizures and global developmental delay on one hand, whereas, it may remain asymptomatic with only skin manifestations on the other hand [14].

In ataxia telangiectasia, the most prominent clinical features are progressive cerebellar ataxia, oculocutaneous telangiectasias, chronic sinopulmonary disease, a high incidence of malignancy and variable humoral and cellular immunodeficiency [13]. Telangiectasia are visible small blood vessels (capillaries, venules and arterioles) over skin and mucosa are also cutaneous marker for underline hereditary disorders [12,13]. In the present case series, Case 5 had all these three components ocular telangiectasias, childhood ataxia with progressive neuromotor degeneration with low IgA (reported in 50-80% of these patients) and high alpha fetoprotein [14].

CONCLUSION(S)

Paediatricians should develop a clinical eye to identify neurocutaneous markers in children, who may arrive at their clinic with various problems for early diagnosis of various neurocutaneous syndrome and their co-morbidities. Whenever a neurocutaneous markers like vascular malformation, nevus, CALM, neurofibroma, facial plaques, port-wine stain is detected, a detailed history including family history should be taken. Thorough clinical examination of all systems is necessary to avoid missing significant early signs. A detailed ophthalmic evaluation of children of all age groups with neurocutaneous marker is a must, including screening for glaucoma and early management to prevent vision loss. Neuroimaging threshold should be low and MRI is preferred. It can reveal many abnormalities which may not be apparent clinically. The present study also highly

recommends the need for regular follow-up with clinical, as well as, ophthalmic, neurological (including neuroimaging when required), cardiac and renal assessment for the neurocutaneous syndromes, when detected.

REFERENCES

- [1] Elshazly M, Lopez MJ, Reddy V, et al. Embryology, Central Nervous System. [Updated 2022 Apr 5]. In: StatPearls [Internet]. Treasure Island (FL): StatPearls Publishing; 2022 Jan-. Available from: <https://www.ncbi.nlm.nih.gov/books/NBK526024/>.
- [2] Sahin M, Ullrich N, Srivastava S, Pinto A. Neurocutaneous Syndromes. In: Shah SS, Tasker RC, Wilson KM, Behrman RE (Eds). Nelson Textbook of Pediatrics. 21st ed. Philadelphia: Elsevier; 2020. Pp. 3146-48.
- [3] Cuccia V, Zuccaro G, Sosa F, Monges J, Lubienieki F, Taratuto AL. Subependymal giant cell astrocytoma in children with tuberous sclerosis. Childs Nerv Syst. 2003;19(4):232-43.
- [4] Pinto A Sturge. Weber Syndrome. In: Shah SS, Tasker RC, Wilson KM, Behrman RE (Eds). Nelson Textbook of Pediatrics. 21st ed. Philadelphia: Elsevier; 2020. Pp. 3146-48.
- [5] Srivastava S, Sahin M. Tuberous Sclerosis. In: Shah SS, Tasker RC, Wilson KM, Behrman RE (Eds). Nelson Textbook of Pediatrics. 21st ed. Philadelphia: Elsevier; 2020. Pp. 3144-46.
- [6] Jain G, Jain VK, Sharma IK, Sharma R, Saraswat N. Neurofibromatosis type 1 presenting with ophthalmic features: A case series. J Clin Diagn Res. 2016;10(11):SR01-SR03. Doi: 10.7860/JCDR/2016/21041.8780. Epub 2016 Nov 1. PMID: 28050470; PMCID: PMC5198423.
- [7] Chhabria BA, Subramaniam PB, Nampoothiri R, Bhalla A, Varma S. Sturge-Weber Syndrome. J Clin Diagn Res. 2017;11(2):OJ05-OJ06. Doi: 10.7860/JCDR/2017/22731.9378. Epub 2017 Feb 1. PMID: 28384923; PMCID: PMC5376883.
- [8] Shaikh SM, Goswami M, Singh S, Singh D. Sturge-Weber syndrome-A case report. J Oral Biol Craniofac Res. 2015;5(1):53-56. Doi: 10.1016/j.jobcr.2015.01.002. Epub 2015 Feb 19. PMID: 25853049; PMCID: PMC4382502.
- [9] Mulkalwar A, Mondkar S, Agrawal M. Importance of family history and clinical examination in evaluation of paediatric brain tumours- A unique case report of tuberous sclerosis. J Clin Diagn Res. 2022;16(7):SD01-SD03. Doi: 10.7860/JCDR/2022/55231.16560.
- [10] Khanna PC, Godinho S, Pungavkar SA, Patkar DP. Ultrafast MRI in the prenatal diagnosis of Bourne ville's tuberous sclerosis. Neurol India. 2005;53(3):349-50.
- [11] Huson SM, Compston DA, Clark P, Harper PS. A genetic study of von Recklinghausen neurofibromatosis in south east Wales I. J Med Genet. 1989;26:704-11.
- [12] Viskochil D, Buchberg AM, Xu G, Cawthon RM, Stevens J, Wolff RK, et al. Deletions and a translocation interrupt a cloned gene at the neurofibromatosis type 1 locus. Cell. 1990;62(1):187-92. Doi: 10.1016/0092-8674(90)90252-a. PMID: 1694727.

- [13] Rothblum-Oviatt C, Wright J, Lefton-Greif MA, McGrath-Morrow SA, Crawford TO, Lederman HM. Ataxia telangiectasia: A review. *Orphanet J Rare Dis.* 2016;11(1):159. Doi: 10.1186/s13023-016-0543-7. PMID: 27884168; PMCID: PMC5123280.
- [14] Sullivan KE, Buckley RH. Combined Immunodeficiency. In: Shah SS, Tasker RC, Wilson KM, Behrman RE (Eds). *Nelson Textbook of Pediatrics.* 21st ed. Philadelphia: Elsevier; 2020. Pp.1117-1118.

PARTICULARS OF CONTRIBUTORS:

1. Assistant Professor, Department of Paediatrics, Jagannath Gupta Institute of Medical Sciences and Hospital, Kolkata, West Bengal, India.
2. Assistant Professor, Department of Paediatrics, Institute of Child Health (ICH), Kolkata, West Bengal, India.
3. Professor and Head, Department of Paediatrics, Jagannath Gupta Institute of Medical Sciences and Hospital, Kolkata, West Bengal, India.

NAME, ADDRESS, E-MAIL ID OF THE CORRESPONDING AUTHOR:

Bibekananda Mukherjee,
Flat No. 1E-102, Alaktika Housing Complex, Action Area-2, Newtown,
Near City Centre 2 Mall, North 24 Parganas, Kolkata, West Bengal, India.
E-mail: bmtata@gmail.com

PLAGIARISM CHECKING METHODS: [\[Jain H et al.\]](#)

- Plagiarism X-checker: Dec 22, 2022
- Manual Googling: Mar 08, 2023
- iThenticate Software: Mar 29, 2023 (5%)

ETYMOLOGY: Author Origin**AUTHOR DECLARATION:**

- Financial or Other Competing Interests: None
- Was informed consent obtained from the subjects involved in the study? Yes
- For any images presented appropriate consent has been obtained from the subjects. Yes

Date of Submission: **Dec 21, 2022**Date of Peer Review: **Feb 04, 2023**Date of Acceptance: **Apr 01, 2023**Date of Publishing: **May 01, 2023**