



Cystic Lymphangioma of the Jejunal Mesentery in a Child

Sopan N. Jatal^{a*}, Sudhir Jatal^b and Sachin Ingle^{c++}

^a Jatal Hospital and Research Centre, Latur, India.

^b Jatal Hospital and Research Centre, Latur, Tata Hospital, Mumbai, India.

^c Department of Pathology, MIMSR Medical College, Latur, India.

Authors' contributions

This work was carried out in collaboration among all authors. All authors read and approved the final manuscript.

Article Information

Open Peer Review History:

This journal follows the Advanced Open Peer Review policy. Identity of the Reviewers, Editor(s) and additional Reviewers, peer review comments, different versions of the manuscript, comments of the editors, etc are available here: <https://www.sdiarticle5.com/review-history/103228>

Case Study

Received: 23/05/2023
Accepted: 12/07/2023
Published: 21/07/2023

ABSTRACT

Mesenteric cystic Lymphangioma are rare intra-abdominal benign tumours of the lymphatic vessels with an incidence of 1:250,000 hospital admission. Representing 5-6% of pediatric benign tumours with a male predominance. It is commonly found in children's appearing at 60% birth and 40% by 2 years of age. A literature review of the studies of mesenteric cystic lymphangioma revealed that only 19% cases were reported from 1960 to 2009.

The cystic lymphangioma consists of dilated lymphatic vessels but lacks connection to the adjacent normal lymphatic spaces. Clinical presentation of mesenteric cystic lymphangioma are asymptomatic abdominal mass to symptomatic of an acute abdomen or intestinal obstruction due to volvulus.

Herein we report a rare case of a huge mesenteric cystic lymphangioma of the Jejunum mesentery in a 5 years old boy. Presenting with asymptomatic palpable abdominal mass in the epigastric and umbilical region. Mesenteric lymphangioma is an extremely rare entity. Total surgical excision of the small bowel along with the huge cystic mass and jejuno-ileal anastomosis.

⁺⁺ Fellow in Colorectal Cancer, Professor;

*Corresponding author: E-mail: jatalhospital@gmail.com;

Keywords: Asymptomatic abdominal mass; mesenteric cystic lymphangioma.

1. INTRODUCTION

“Mesenteric cystic lymphangioma is rare benign cystic neoplasm originating from the lymphatic system and commonly found in children. The most common cystic tumours is in the head and neck 70%, axilla 20% and internal organs 10%. Diagnosis is confirmed by histopathological findings [1,2].

“Mesenteric lymphangioma is extremely rare and accounts for less than 1% of abdominal lymphangioma. Although they can be asymptomatic and detected incidentally. Common symptoms include a palpable abdominal mass, abdominal pain and acute intestinal obstruction due to volvulus. The most common location include small bowel mesentery 70% and the mesentery of mesocolon and retroperitoneum 30%” [1,2,3,4,5].

“Lymphangiomas are traditionally classified in to three histologic types.

1. Capillary
2. Cavernous
3. Cystic lymphangiomas” [1].

“Although benign lymphangiomas can cause other symptoms such as bleeding, torsion or rupture of lymphangioma. Acute abdominal symptoms that require emergency surgery. Surgical segmental bowel resection along with mesenteric cystic mass is the ideal treatment” [2,6].

2. CASE REPORTS

A 5 years old boy was admitted to our centre in 12/08/2009. Physical examination showed a huge palpable mass at epigastric and umbilical region, mobile and accompanied by tenderness. The laboratory investigation was normal. Ultrasonography abdomen showed an intra-abdominal Multilocular cystic mass with liquid fluid inside the cysts.

Laparotomy was performed. During the operation a huge multilocular cystic mass measuring 15x12x10 cm attached with jejunal mesentery. The tumour was located 15 cm from the Treitz ligament which revealed a giant multilobulated

cystic mass. The cystic mass protruded from both side to the mesentery and each cyst measured 4-5 cm in size, spherical shape and containing milky white fluid filled cystic mass in the mesentery of jejunum and ileum. The big multilobular cystic mass was excised completely with 15 cm segment of jejunum and jejuno-ileal anastomosis was done. The operation procedure was uneventful with minimal blood loss and took only one and half hours to complete the operation. The procedure was well tolerated by the child without any postoperative complication.

On gross a big multilobulated cystic mass, weight 1.5 kg and size of 15x12x10 cm. Each cyst nodule 4-5 cm in size, spherical in shape and white in colour containing white milky fluid. Histopathological report was multilocular cystic lymphangioma. At 5 years follow up, child was in good condition and there was no recurrence. (Figs. 1, 2, 3, 4).

3. DISCUSSION

“Lymphangioma of the jejunal mesentery are extremely rare accounting for less than 1% of all lymphangioma. Lymphangioma are congenital malformations of the lymphatic vessels, formed due to sequestration of lymphatic vessels during the embryonic period. However, some data suggest the inflammation, abdominal trauma, abdominal surgery, radiation or lymphatic obstruction may play the role in the genesis of lymphatic tumours” [2,3,5].

“Clinical presentation of mesenteric lymphangiomas are asymptomatic abdominal masses, acute abdomen or intestinal obstruction in the form of small bowel volvulus. Although benign lymphangiomas can cause other symptoms such as bleeding, torsion and lymphatic rupture, needs emergency explorative laparotomy” [1,5].

Lymphangiomas are traditionally classified into three histologic type, capillary, cavernous and cystic lymphangiomas. The cystic lymphangioma consists of dilated lymphatic spaces of various size but lacks communication to the normal lymphatic channels. Resent classification of mesenteric cystic lymphangioma in to four types.

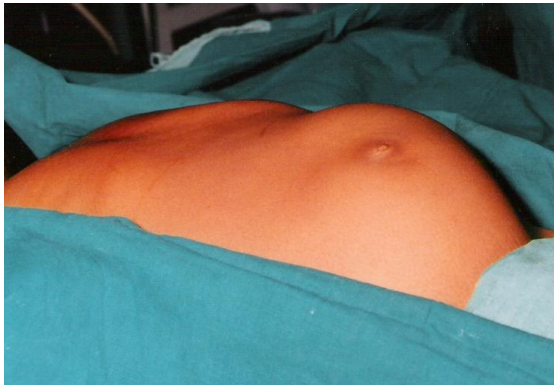

Fig. 1. A palpable lump in abdomen occupying suprapubic, umbilical and epigastric region of lump size 10x8 cm

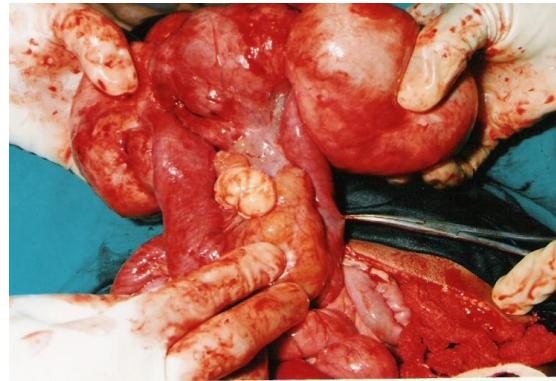


Fig. 2. Intraoperative photographs showing a huge chylolymphatic multicystic mass arising from the jejunal mesentery

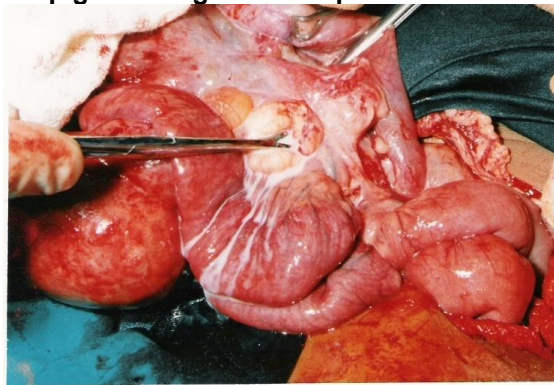


Fig. 3. Intraoperative photographs showing a huge chylolymphatic multicystic mass, milky white fluid oozing from the cyst

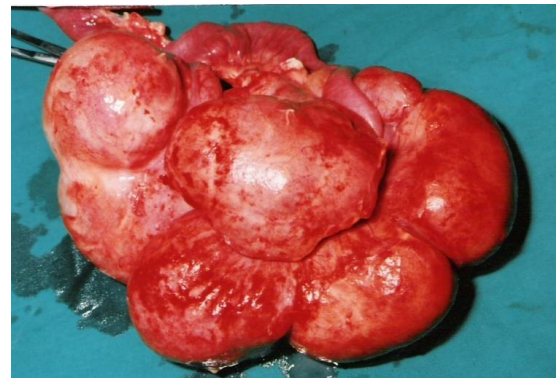

Fig. 4. Showing a huge chylolymphatic multicystic mass of size 15x12x10 cm & weight 1.5 kg

Type 1- Pedicel mesenteric cystic lymphangioma can cause intestinal volvulus and torsion.

Type 2- Sessile mesenteric cystic lymphangioma, which is near to mesenteric border.

Type 3- Mesenteric cystic lymphangioma with retroperitoneal extension.

Type 4- Multicentric mesenteric cystic lymphoma, this type is having bad prognosis due to extensive intro-abdominal and retroperitoneal organs involvement [5].

The first choice for diagnosis is ultrasound. Ultrasound can show cystic masses containing fluids. However, ultrasonography and CT scan together are not enough for a preoperative diagnosis. MRI imaging is the most useful tool for diagnosis and surgical planning. A definitive diagnosis is confirmed by histopathology and immunochemistry [4,5].

Surgical segmental bowel resection including the mesenteric cystic mass is the optimal treatment for avoiding recurrence [7-11].

4. CONCLUSION

Mesenteric cystic lymphangioma is a benign disease of lymphatic vessels and is extremely rare. Complete surgical resection of the cystic mass of lymphangioma along with the ileal segment is the ideal modality of treatment. A definitive diagnosis is confirmed by histopathology.

CONSENT

As per international standard or university standard, Parental written consent has been collected and preserved by the author(s).

ETHICAL APPROVAL

As per international standard or university standard written ethical approval has been collected and preserved by the author(s).

COMPETING INTERESTS

Authors have declared that no competing interests exist.

REFERENCES

1. Gunadi, Kashogi G, Prasetya D, Fauzi AR, Daryanto E, Dwihtoro A. Pediatric patients with mesenteric cystic lymphangioma: A case series. *Int J Surg Case Rep.* 2019;64:89-93. DOI: 10.1016/j.ijscr.2019.09.034. Epub 2019 Oct 1. PMID: 31622933; PMCID: PMC6796738.
2. Heredea R, Cimpean AM, Cerbu S, Popoiu CM, Jitariu AA, Raica M. New approach to rare pediatric multicystic mesenteric lymphangioma; Would It guide the development of targeted therapy? *Front Pediatr.* 2018;6:223. DOI: 10.3389/fped.2018.00223. PMID: 30131951; PMCID: PMC6090038.
3. Altijani AM, Abdul-Rahim Muhammad T. Mesenteric cystic lymphangioma in an 11-month infant: A case report. *World J Surg Surgical Res.* 2020;3:1245.
4. Yosra Kerkeni, Arije Zouaoui, Fatma Thamri, MD, Cystic lymphangioma of the small bowel mesentery in a child. *The Journal of Pediatrics.* Available: <https://doi.org/10.1016/j.jpeds.2021.12.032>
5. Sushma Thapa, Abhinav Sharma, Dipesh Upreti, Om Bahadur Karki, Sudeep Regmi, Dilasma Ghartimagar, Arnab Ghosh. A huge mesenteric lymphangioma presenting as a small bowel volvulus in a paediatric patient: A case report. *Case Reports in Pathology.* 2022; Article ID 3033705:5 pages. Available: <https://doi.org/10.1155/2022/3033705>
6. Niharika Prasad. Abdominal cystic lymphangioma in a child, *EuroRad.* DOI: 10.35100/euroRad/case.17259
7. Sosnowska-Sienkiewicz P, Miedziarek C, Mańkowski P. A rare presentation of mesenteric cystic lymphangioma in 5-year-old girl. *Pediatrics Polska - Polish Journal of Paediatrics.* 2021;96(4):285-287. DOI:10.5114/polp.2021.109297
8. Prashant V, Madhu K, Rawat JD. A huge cystic mesenteric lymphangioma of small intestine involving ileum: An unusual cause of abdominal pain. *Am J Clin Case Rep.* 2022;3(4):1069.
9. Ali HA, Zerouh B, Bouzayan L, Jabi R, Bouziane M. Giant cystic lymphangioma of the stomach: A case report. *Ann Med Surg (Lond).* 2020;61:8-12.
10. Lui SA, Nyo YL, Mali VP. Ileal cystic lymphangioma presenting with acute appendicitis. *J Indian Assoc Pediatr Surg.* 2018;23:36-38
11. Konen O, Rathaus V, Dlugy E, Freud E, Kessler A, Shapiro M, et al. Childhood abdominal cystic lymphangioma. *Pediatr Radiol.* 2002;32:88-94.

© 2023 Jatal et al.; This is an Open Access article distributed under the terms of the Creative Commons Attribution License (<http://creativecommons.org/licenses/by/4.0>), which permits unrestricted use, distribution, and reproduction in any medium, provided the original work is properly cited.

Peer-review history:

The peer review history for this paper can be accessed here:
<https://www.sdiarticle5.com/review-history/103228>