

## Management of Tongue Tie Using Diode Laser: A Case Report

Keerti Rawat <sup>a\*#</sup>, Kabyik Goldar <sup>a‡</sup>, Prakriti Chaudhary <sup>a#</sup> and Dileep Kishore <sup>a#</sup>

<sup>a</sup> Department of Periodontology, Teerthanker Mahaveer Dental College and Research Centre, Moradabad, Uttar Pradesh, India.

### Authors' contributions

*This work was carried out in collaboration among all authors. All authors read and approved the final manuscript.*

### Article Information

#### Open Peer Review History:

This journal follows the Advanced Open Peer Review policy. Identity of the Reviewers, Editor(s) and additional Reviewers, peer review comments, different versions of the manuscript, comments of the editors, etc are available here: <https://www.sdiarticle5.com/review-history/87775>

**Received 25 March 2022**

**Accepted 04 June 2022**

**Published 11 June 2022**

**Case Study**

## ABSTRACT

**Background:** Tongue tie, also known as ankyloglossia, is a congenital disorder that occurs when the inferior lingual frenulum is too short and shows attachment to the tip of the tongue, preventing normal tongue motions. Ankyloglossia can lead to a range of problems such as speech impediments, difficulties in breast feeding, malocclusion, poor oral hygiene, inability in deglutition, thus being an undesired problem in normal life activity. Various techniques like scalpel, laser and electro-surgery have been performed in treating tongue tie. Though each technique has its own advantages and disadvantages, aim of all the treatment procedures is to relieve the high muscle attachment to improve the movement of the tongue.

**Case presentation:** A male patient aged ten came with a chief complaint of difficulty in speech to the department of periodontology. On examination presence of tongue tie was observed. For which complete blood profile got investigated, followed by treatment protocol which included oral hygiene instructions, oral prophylaxis and surgical relieving of the aberrant lingual frenum using laser.

**Result:** Uneventful healing was observed with minimal pain experienced by the participating subject. Free movement of the tongue upto the normal range was observed after suture removal.

**Conclusion:** Speech difficulty and limitation of tongue movement makes it difficult for the patient's having tongue tie. So, in order to remedy the condition, therapy should be administered on time and can be enhanced by surgical operations.

# Post graduate student

‡ Senior Lecturer

\*Corresponding author: Email: keertinisha.rawat@gmail.com;

**Keywords:** Lingual Frenulum; frenectomy; ankyloglossia; tongue tie; laser.

## 1. INTRODUCTION

“The term ankyloglossia is derived from the Greek words skolios (curved) and glossa (tongue). The tongue is a muscle organ that influences speech, tooth position, periodontal tissue, nutrition, and swallowing. Tongue tie is a non-medical word for the same disorder that restricts the function of the tongue. Ankyloglossia, often known as tongue-tie, is a congenital disorder caused by an improper contact between the tongue and the floor of the mouth, resulting in an unusually short tongue” [1,2]. “There is a distinctively short and thick lingual frenum that restricts tongue mobility. This defect can sometimes self-correct; as a kid grows older, the frenum recedes to a lower position, enhancing tongue movement” [3]. “The prevalence of ankyloglossia in the general population ranges between 4.2 and 10.7 percent. It is more prevalent in men, with a male to female ratio of 2.5:1.0. Ankyloglossia can manifest as a single entity or as a component of other rare syndromes such as i) Smith-Lemli-Opitz syndrome, ii) Orofacial digital syndrome, iii) Beckwith Weidman syndrome, iv) Simpson-golabi-behmel syndrome, v) X-linked cleft palate syndrome, vi) Kindler syndrome, and vii) Van der Woude syndrome. Opitz syndrome, Ehlers Danlos syndrome, Beckwith Wiedemann syndrome, Simosa syndrome, and so on. It is also common in children whose mothers take drug cocaine” [4,5].

## 2. CASE REPORT

A 10-year-old child presented to the periodontology department with the major complaint of difficulty in speaking due to an inability to move his tongue freely. The patient was aware and cooperative, walking normally and vital parameters were within the limits. Extraoral examination revealed no notable results, however intraoral examination indicated that the frenum extended from the ventral side of the tongue to the lingual gingiva of the anterior part of lower jaw. During the examination, the patient was unable to lift his tongue to touch his palate. There was no malocclusion in this instance, although there was recession lingual to the mandibular incisors. Tongue mobility was restricted due to the fusion of the lingual frenulum to the tongue, with only a 3-7mm protrusion. It was determined that the patient had severe ankyloglossia (Figs. 1&2: Class II Kotlow's categorization) [1].

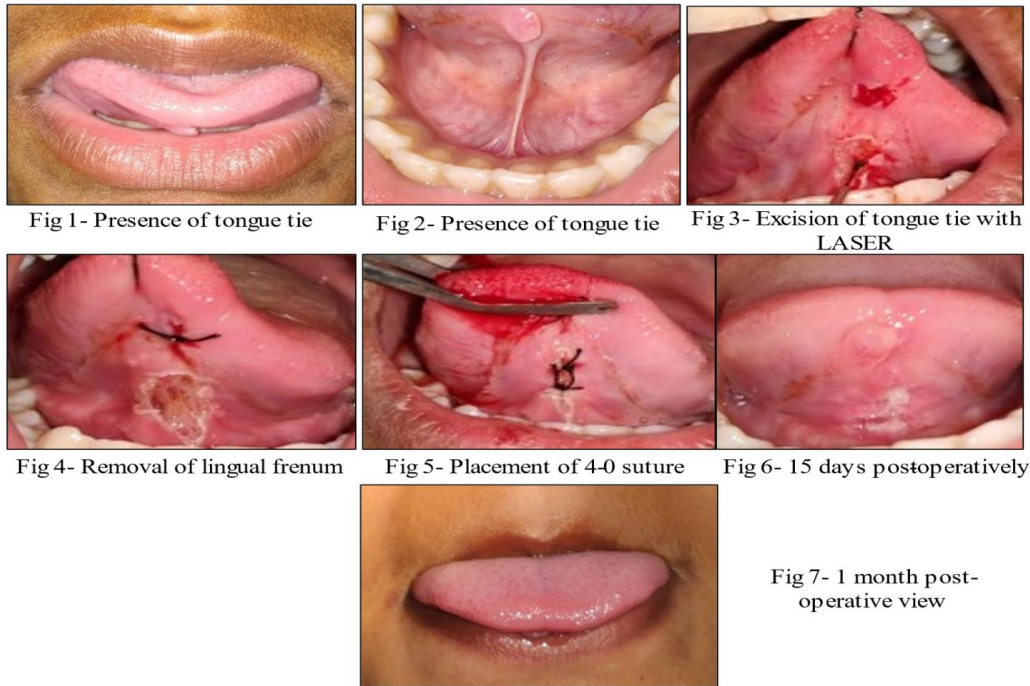
## 3. TREATMENT PROCEDURE

After ensuring proper antisepsis, L.A., lignocaine (1:80000) was given for better During the process, pain is managed. While executing the surgery, the tongue was stabilised. Indelible pencil was employed to outline future regions of cut incisions. Measures were attempted to safeguard and prevent unnecessary injury and surgical difficulties to critical anatomical landmarks such as the submandibular and sublingual ducts and lingual arteries. Dissection was performed through the submucosa and muscle layer; afterwards tongue mobility was evaluated for amount of tongue releasing (Fig. 4). In non-contact mode, a diode laser with a wavelength of 870 nm and a power of 2 W was employed. Suturing on many layers with 4-0 silk sutures involving muscles and submucosa was contemplated. The sutures were removed one week following surgery, indicating satisfactory healing, and the tongue motions were re-evaluated (Figs. 3-7) and before freeing the patient, the patient's haemostasis was assessed. The patient was given antibiotics and painkillers, as well as oral hygiene instructions and many tongue exercises.

The patient was recalled 15 days and 1 month following surgery. The mobility of the tongue has improved (Fig. 6). Speech treatment also resulted in syllable improvement.

## 4. DISCUSSION

“Ankyloglossia (developmental abnormality) characterised by a small lingual frenulum and tongue adhesion to the floor of the mouth. This is due to cellular degeneration failure, which results in a considerably longer anchor between the floor of the mouth and the tongue [6]. This anomaly's pathogenesis is unclear. Ankyloglossia is associated with a number of uncommon diseases, including X-linked cleft palate (OMIM 303400) [7]. and van der Woude syndrome (OMIM 119300)” [8]. Opitz syndrome [9] and Kindler syndrome are two examples [10]. It is frequently encountered as an isolated discovery in a normally developing youngster. The reported incidence rates varied from 0.02 percent to 4.8 percent of new – borns [11]. Several categorization have been proposed, but none has gained widespread acceptance. Kotlow's classification may be used to classify [12] Tongue Ties (Table 1) [13]. Management is



**Table 1. Kotlow’s classification to distinguish severity of ankyloglossia**

<b>Kotlow’s Classification (1999)</b>		
<b>Clinically acceptable</b>	Normal Range Of Free Tongue Movement	> than 16 mm
<b>Class I:</b>	Mild Ankyloglossia	12-16 mm
<b>Class II:</b>	Moderate Ankyloglossia	8-11 mm
<b>Class III:</b>	Severe Ankyloglossia	3-7 mm
<b>Class IV:</b>	Complete Ankyloglossia	< than 3mm

determined by prompt and adequate surgery, followed by speech therapy, which produces satisfactory outcomes in less time than predicted. There are three types of surgical methods for ankyloglossia: (i) Frenotomy is a simple cutting of the frenulum; (ii) frenectomy is a complete excision of the frenulum; and (iii) frenuloplasty involves numerous procedures to relieve the ankyloglossia and fix the anatomic position [14]. Traditional scalpel surgery, electrocautery [15], and laser surgery are all options for treating ankyloglossia. There will be no discernible improvement in speech without post-operative tongue training. It enhances sense of tongue regions (kinaesthesia) and rapid alternating tongue motions (dia-do-chokinesis) [16]. In our situation, a laser frenectomy was planned since surgical removal of the muscle fibres, thereby releasing the frenulum, was straightforward, simpler, and less time consuming. The most advantageous aspect of using laser over other procedures was the ability to completely liberate the lingual frenulum muscle fibres. However, extreme caution should be exercised when

employing laser to avoid harm to nearby important tissues. In this example, the frenectomy resulted in satisfactory healing with no post-operative problems.

## 5. CONCLUSION

Tongue tie inhibits an individual's functioning abilities and promotes social shame owing to a communication difficulty. For which correction, such as combined surgical surgery and speech therapy, should be preferred.

## CONSENT

As per international standard or university standard, patients’ written consent has been collected and preserved by the author(s).

## ETHICAL APPROVAL

As per international standard or university standard written ethical approval has been collected and preserved by the author(s).

## COMPETING INTERESTS

Authors have declared that no competing interests exist.

## REFERENCES

1. Hasan A, Cousin G. Ankyloglossia (tongue-tie). Afr J Paediatr Surg. 2015;12(1):101.
2. Reddy NR, Marudhappan Y, Devi R, et al. Clipping the (tongue) tie. J Indian Soc Periodontol. 2014;18(3):395-8.
3. Junqueira MA, Cunha NN, Costa e Silva LL, et al. Surgical techniques for the treatment of ankyloglossia in children: A case series. J Appl Oral Sci. 2014;22(3):241-8.
4. Bai PM, Vaz AC. Ankyloglossia among children of regular and special schools in Karnataka, India: A prevalence study. J Clin Diagn Res. 2014;8(6):ZC36-8.
5. Wieker H, Sieg P. Ankyloglossia superior syndrome: case report and review of publications. Br J Oral Maxillofac Surg. 2014;52(5):464-6.
6. Morowati S, Yasini M, Ranjbar R, Peivandi AA, and Ghadami M. Familial Ankyloglossia (Tongue-tie): A Case Report. Acta Med Iran. 2010;48:123-124.
7. Moore GE, Ivens A, Chambers J, Farrall M, Williamson R, Page DC, et al. Linkage of an X-chromosome cleft palate gene. Nature 1987; 326: 91-92.
8. Burdick AB, Ma LA, Dai ZH, Gao NN. van der Woude syndrome in two families in China. J Craniofac Genet Dev Biol. 1987;7:413-418.
9. Brooks JK, Leonard CO, Coccaro PJ Jr. Opitz (BBB/G) syndrome: Oral manifestations. Am J Med Genet. 1992;43:595-601.
10. Hacham-Zadeh S, Garfunkel AA. Kindler syndrome in two related Kurdish families. Am J Med Genet. 1985;20:43-8.
11. Messner AH, Lalakea ML, Aby J, Macmahon J, Bair E. Ankyloglossia: Incidence and associated feeding difficulties. Arch Otolaryngol Head Neck Surg. 2000;126:36-39.
12. Suter VG and Bornstein MM. Ankyloglossia: Facts and Myths in Diagnosis and Treatment. J Periodontol. 2009; 80:1204-1219.
13. Kotlow LA. Ankyloglossia (tongue-tie): A diagnostic and treatment quandary. Quintessence Intl. 1999;30:259-62.
14. Tuli A, Singh A. Monopolar diathermy used for the correction of ankyloglossia. J Indian Soc Pedod Prev Dent. 2010;28(2):130-3.
15. Darshan HE, Pavithra PM. Tongue tie: From confusion to clarity-A review. Int J Dent Clin. 2011;3(1):48-51.
16. Bhattad MS, Baliga MS and Kriplani R. Clinical guidelines and management of ankyloglossia with 1-year follow up: Report of 3 cases. Case Reports in Dentistry. 2013; 2013:185803.

© 2022 Rawat et al.; This is an Open Access article distributed under the terms of the Creative Commons Attribution License (<http://creativecommons.org/licenses/by/4.0>), which permits unrestricted use, distribution, and reproduction in any medium, provided the original work is properly cited.

*Peer-review history:*

*The peer review history for this paper can be accessed here:*  
<https://www.sdiarticle5.com/review-history/87775>