

Assessment of *Urtica Aestuans* Extract on Ulcer Indices and Histology of Indomethacin Induced Gastric Toxicity

Nwafor C. Charles^{a*}, Ugwuishi E. Williams^b, Izunwanne I. Desmond^c and Okeke O. Cynthia^a

^a Department of Human Physiology, School of Basic Medical Sciences, College of Health Sciences, Igbinedion University, Okada, Nigeria.

^b Department of Human Physiology, Faculty of Basic Medical Sciences, College of Medicine, Enugu State University, Parklane, Enugu, Nigeria.

^c Department of Human Physiology, Faculty of Basic Medical Sciences, College of Medicine, Imo State University, Owerri, Nigeria.

Authors' contributions

This work was carried out in collaboration among all authors. All authors read and approved the final manuscript.

Article Information

Open Peer Review History:

This journal follows the Advanced Open Peer Review policy. Identity of the Reviewers, Editor(s) and additional Reviewers, peer review comments, different versions of the manuscript, comments of the editors, etc are available here: <https://www.sdiarticle5.com/review-history/91698>

Original Research Article

Received 07 August 2022
Accepted 10 October 2022
Published 14 November 2022

ABSTRACT

The effectiveness of *Urtica aestuans* hydro-ethanolic leaf extract on ulcer indices and histopathology in Wistar rats was investigated in the current study. For this investigation, 30 rats were utilized, divided into 6 groups of 5 rats each. Groups 1 and 2 functioned as the control group (CG) and Indomethacin only group (INDOG - 40mg/kg), Group 3 as the standard drug group (SDG - 200mg/kg), Group 4 as the low dosage extract group (LDEG - 50mg/kg), Group 5 as the medium dose extract group (MDEG - 75mg/kg), and Group 6 as the high dose extract group (HDEG - 200mg/kg) respectively. All the rats received treatment for 14 days before being fasted for 24 hours with unlimited access to water. After a 24-hours fast, 40mg/kg of indomethacin was administered orally to induce gastric ulcers. The leaves of *Urtica aestuans* significantly ($P < 0.05$) decreased ulcer indicators such as volume of gastric juice, stomach acidity, ulcer index, percentage ulcer inhibition, and gastric pH. MDA significantly decreased as SOD, CAT and GSH levels increased significantly

*Corresponding author: E-mail: nwaforcharles3@gmail.com;

in the extract groups when compared to indomethacin only group (IOG). The acquired data suggests that the antioxidant properties of the plant extract and its active ingredients are responsible for the anti-ulcer actions of *Urtica aestuans* leaf extract.

Keywords: *Urtica aestuans*; indomethacin; ulcer indices; gastric toxicity.

1. INTRODUCTION

The most prevalent gastrointestinal and international disorder is stomach ulcers. It happens mostly as a result of an imbalance between the mucosal barrier's offensive and destructive elements [1]. Stomach hydrochloric acid (HCl), mucosal hypoperfusion, free radicals, liquor, *Helicobacter pylori*, and excessive use of non-steroidal anti-inflammatory drugs (NSAIDs), which encourage gastric mucosal damage and gastric ulcers, are among the damaging causes [2]. A medical problem is preventing or treating stomach ulcers. Major drawbacks of gastric ulcer therapy include the ineffectiveness of medications to treat the condition and severe side effects [3,4].

A potential alternative medicine that has fewer adverse effects and contains a variety of antioxidants may therefore be found in medicinal plants. According to a thorough literature analysis, medicinal plants are also promising complementary treatments for the creation of novel pharmaceuticals to control gastrointestinal illnesses [5].

Laportea aestuans is another name for the tropical and subtropical plant known as *Urtica aestuans* (family Urticaceae). This medicinal plant is used to treat hernias, fevers, and oedema in addition to preventing amenorrhea. Previous research has demonstrated that this plant has antibacterial, antifungal, and antioxidative properties. Additionally, *U. aestuans* extract may promote fertility and aphrodisiac activities [6]. Traditional medicine practitioners in Nigeria utilize this plant as antacids in ulcer patients. However, we still need to conduct suitable trial studies to fully understand the positive effects of *U. aestuans* leaf extract on stomach cytoprotective characteristics. In order to evaluate the gastroprotective effect of *U. aestuans* hydroethanolic extract against indomethacin-induced stomach ulcers in rodents, the current study was conducted.

2. MATERIALS AND METHODS

2.1 Preparation of Extract

The Department of Plant Sciences, Faculty of Sciences, University of Port-Harcourt, Choba, Nigeria's botanic homestead, provided fresh leaves of *Urtica aestuans*, which were then collected and identified scientifically by the herbarium. The leaves were properly cleaned before being allowed to air dry. Using a Soxhlet apparatus 650 g of the dry powdered leaves were defatted and sequentially extracted in 400ml of hydro-ethanol mixture (30:70) for 72 hours in an extraction jar. The extract was concentrated through the use of a rotary evaporator, to yield the crude extract. Until they were used for extract processes, the excellent quality of dried leaves was maintained in a dry plastic container.

2.2 Phytochemical Analysis

The quantitative and qualitative phytochemical analysis of the extract was performed according to the methods of Sofowara [7] with slight modifications. The analysis of phytochemical was performed on a BUCK M910 Gas chromatography equipped with a flame ionization detector using the method of [8].

2.3 Experimental Design

For this investigation, 30 rats were used, divided into 6 groups of 5 rats each. Group 3 – 6 rats received drug and extract therapy for 14 days before being fasted for 24 hours with unlimited access to water. After a 24-hours fast, 40mg/kg of indomethacin was administered orally to cause gastric ulcers in all the test groups except group 1 (CG).

Group 1: Control group (CG), received feed and water *ad libitum* only

Group 2: Indomethacin only group (INDOG), received 40mg/kg of Indomethacin

Group 3: Standard Drug Group (SDG), received 200mg/kg of cimetidine

Group 4: Low dose extract group (LDEG), received 50mg/kg of the extract

Group 5: Medium dose extract group (MDEG), received 75mg/kg of the extract

Group 6: High dose extract group (HDEG), received 200mg/kg of the extract
The extract and cimetidine were administered orally for a period of 14 days.

3. INDUCTION OF GASTRIC ULCER

In accordance with the method outlined by Sayanti et al. [9], intragastric injection of 40 mg/kg of indomethacin to the rats was used to induce gastric hemorrhagic lesions. One hour before the administration of indomethacin, the drugs and extract were given. The animals were anaesthetized and sacrificed by cervical dislocation four hours after receiving indomethacin, and the stomachs were taken out, filled with 1 mL of 1% paraformaldehyde overnight to fix the tissue walls, and cut apart along the larger curvature. The UTHSCSA Image Tool 3.00 was used to calculate the lesion index, and the total erosion length per rat.

4. DETERMINATION OF ULCER INDICES

4.1 Determination of Gastric Juice Volume

Four hours after the gastric ulcer was induced, the rats were sacrificed, and the stomach was removed from the abdomen. To calculate the volume of gastric juice, stomach contents were collected into measuring cylinders.

4.2 Determination of Gastric Acid Secretion

The gastric juice content was mixed with 5ml of distilled water, and the resulting solution was centrifuged at 3,000 rpm for 10 minutes. By titrating the supernatant to pH 7 with 0.0025N sodium hydroxide, the stomach acidity in mEq/L was calculated from the supernatant.

4.3 Determination of Gastric Mean Ulcer Index

Following the removal of the stomach's gastric contents, the stomach was pinned to a board, and the ulcer was then scored as follows:

1 denotes erosions that are less than 1 mm in diameter, 2 denote erosions that are between 1 and 2 mm in diameter, and 3 denotes erosions that are larger than 2 mm in diameter. The ulcer index was calculated by multiplying the sum of the scores by a factor of 10.

4.4 Determination of Percentage Ulcer Inhibition

The percentage of ulcer inhibition was also calculated as follows:

Percent ulcer inhibition = $\frac{\text{mean ulcer index of control} - \text{mean ulcer index of test}}{\text{Mean ulcer index of control}} \times 100$

4.5 Measurement of pH

Using a pre-calibrated Beckman pH meter, samples of gastric contents (1ml) were examined for hydrogen ion concentration. The electrodes were repeatedly washed with distilled water before being calibrated with pH 4 and pH 7 standard buffer solutions.

5. DETERMINATION OF OXIDATIVE INDICES

5.1 Determination of MDA

An aliquot of 0.4ml of supernatant was in mix with 1.6ml of Tris-KCl buffer to which 0.5ml of 30% TCA was added. Then 0.5ml of 0.75% TBA was added and placed in boiling water for 1hr. This was then cooled in ice and centrifuged at 4000 rpm. The clear supernatant was collected and the absorbance measured at 532nm using d/w as blank.

5.2 Determination of SOD

0.2ml of sample was diluted in d/w to make a 1:10 dilution, 200ul of the diluted sample was added to 2.5ml of 0.05m carbonate buffer (pH10.2). The reaction was started by adding 0.3ml of freshly prepared 0.3mm epinephrine to the mixture, which was quickly mixed by inversion. The increase in absorbance was read and recorded at 480nm for 30secs to 2.5mins. Unit: u/ml

5.3 Determination of CAT

0.2ml of sample was added to phosphate buffer containing 100mm of H₂O₂, in a total of 1ml. Incubate for 2mins at 37°C. Changes in absorbance was read and recorded at 240nm, unit u/g

5.4 Determination of GSH

0.2ml of the sample was added to 1.8ml of d/w and 3ml of the precipitating solution and mixed. Allowed to stand for 5 min and centrifuged at 4000rpm for 10mins. 1ml of filtrate was added to 4ml of 0.1m phosphate butter. 0.5ml of DTNB

was finally added. The absorbance was read and recorded at 412nm using a prepared blank to zero the spectrophotometer. unit ug/ml

5.5 Statistical Analysis

The mean and standard error of the mean were used to express the results. With the use of

Students Package for Social Science, version 23.0, data were analyzed using a one-way analysis of variance, followed by the LSD post-hoc test to identify significant differences in all the parameters (SPSS). Differences were deemed statistically significant when their p-values were less than 0.05.

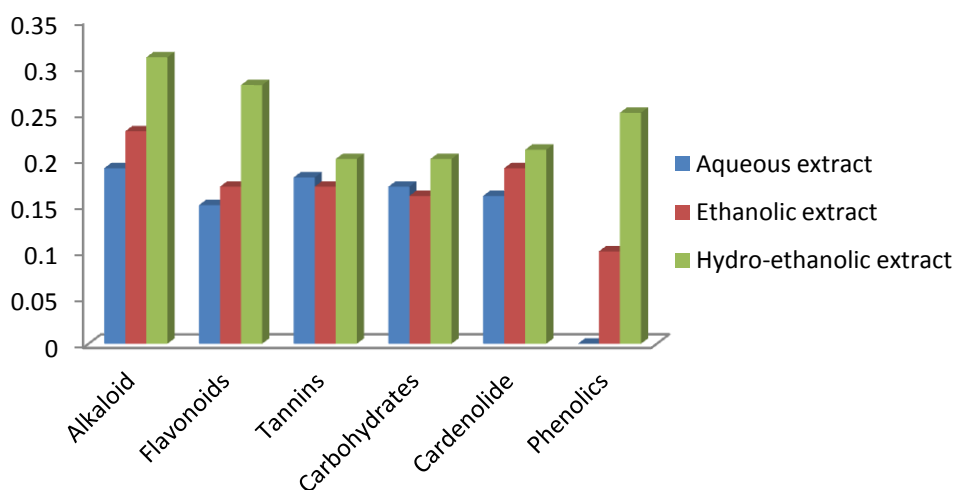


Fig. 1. Quantitative phytochemical screening of the leaves of *Urtica aestuans*

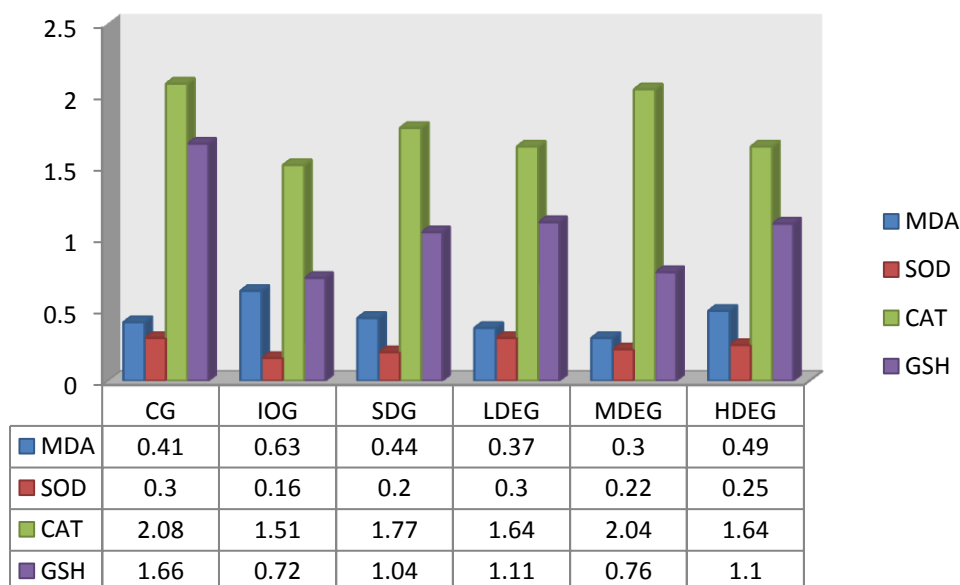


Fig. 2. Oxidative Indices of extract in study animals

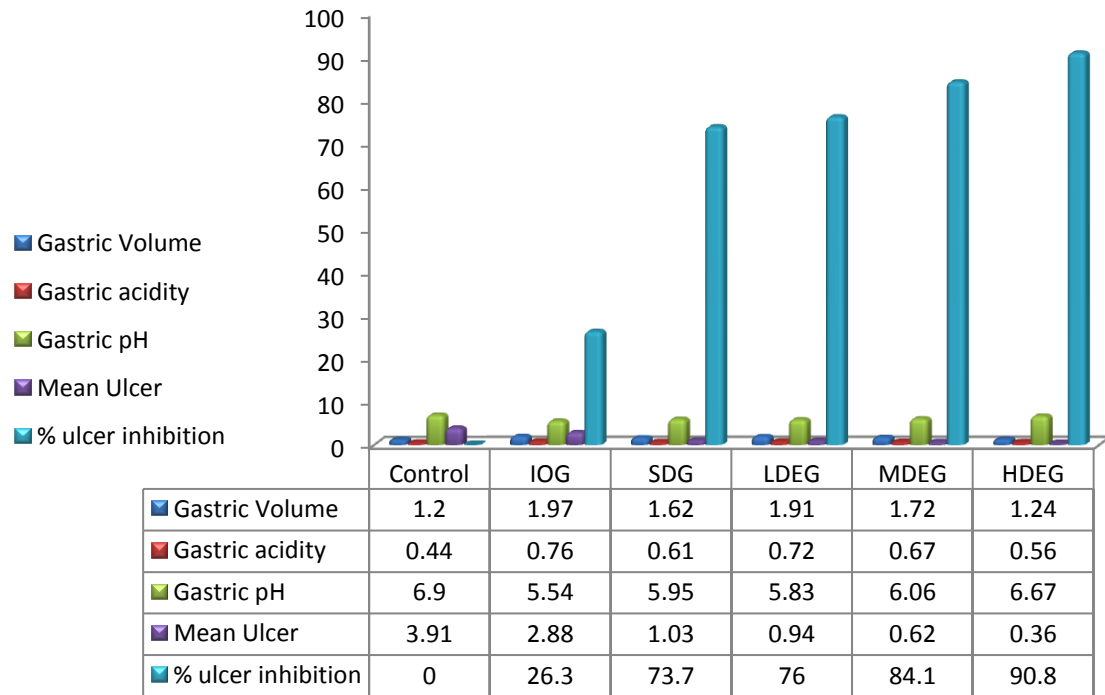


Fig. 3. Values of ulcer parameters of extract in study animals

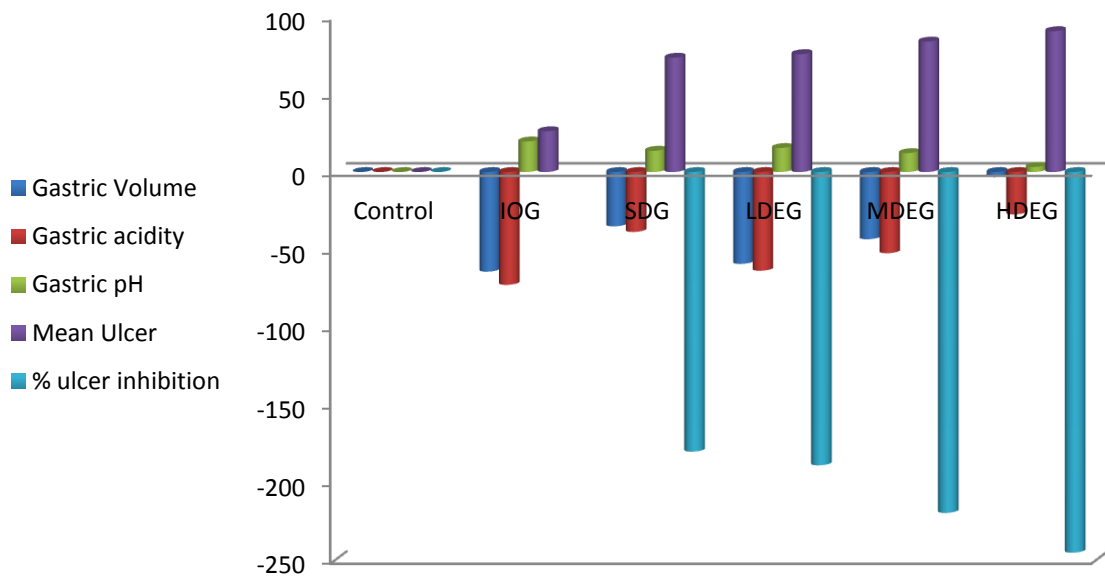
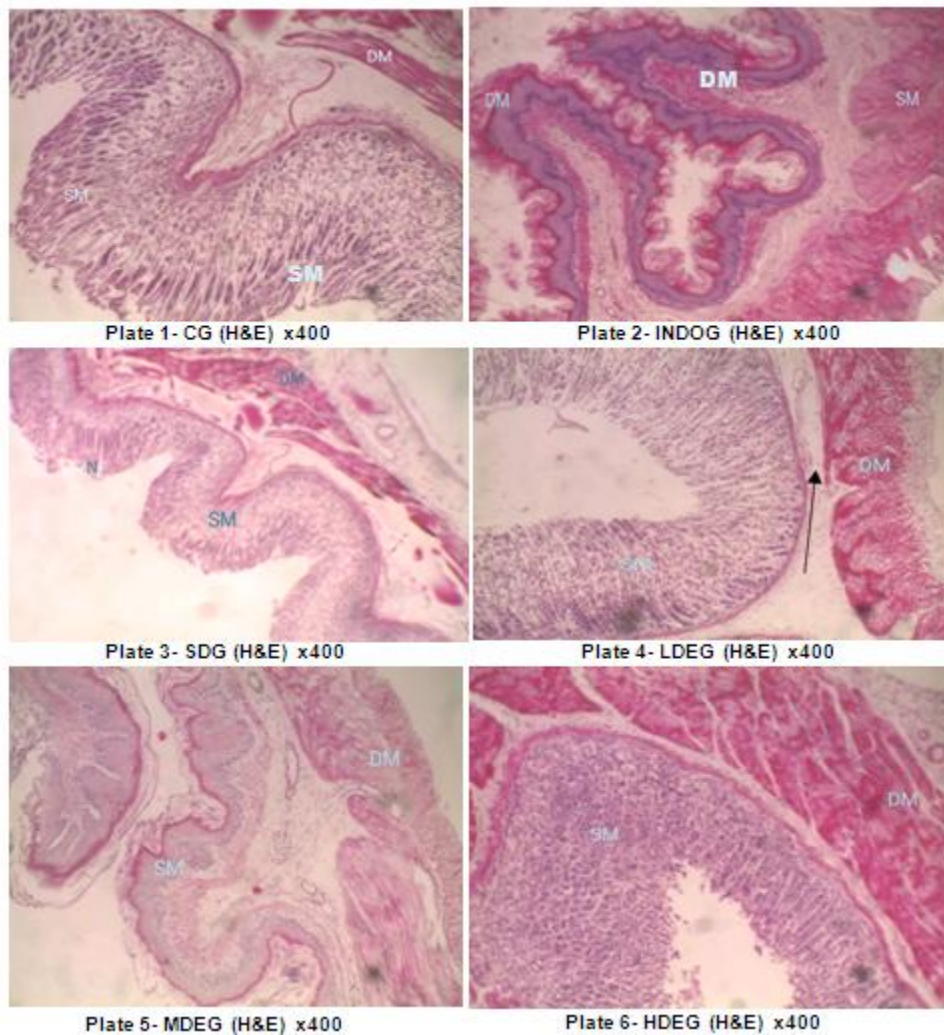


Fig. 4. % diff of ulcer parameters of extract in study animals

Histological Examination



Key: SM= Sub mucosa, DM= Deep Mucosa, In= Infiltration, N= Necrosis

6. RESULTS

The quantitative phytochemical screening of the aqueous, ethanolic and hydro-ethanolic extracts of the *U. aestuans* leaves shows that the combination of water and alcohol (hydro-ethanolic) extract contains more phytoconstituents in contrast to aqueous only extract and ethanolic only extract (Fig. 1). Fig. 2 shows that MDA significantly decreased while SOD, CAT and GSH levels increased significantly in the standard drug group (SDG) and extract groups when compared to indomethacin only group (IOG). Figs. 3 & 4 demonstrated a significant reduction in ulcer indices and percentage ulcer inhibition by the extract in contrast to the indomethacin only group (IOG).

The INDOG's stomach mucosa had extensive damage, according to histology (Plate 2). Gastric mucosal necrosis was present in the ulcerated rat group. In contrast, animals fed with *U. aestuans* extract in the Plates 3–6 groups displayed improved protection of the stomach mucosa with a depressed level of or absence of leucocyte infiltration and edoema. Extracts of *U. aestuans* demonstrated defense actions that were dose-dependent and significantly improved stomach epithelial protection.

7. DISCUSSION

In this study, it was found that treatment with *U. aestuans* leaf extract hastened the healing of ulcers caused by indomethacin in the stomach tissue of rats. Indomethacin-induced stomach

ulcers are comparable to human ulcers in that they manifest in the same region, are as severe and persistent, and progress through a similar healing process [10]. Changes in a variety of variables, including PG production, growth factor, NO, cytokine levels, and mucus formation, lead to the development of ulcers when indomethacin is used to induce them. Oral administration of indomethacin in this study also resulted in significant mucosal disruption, loss of normal colour, hemorrhage, oedema, and other macroscopic damage to the stomach mucosa layer. By blocking the production of PGs by cyclooxygenase-1 (COX-1) and causing oxidative stress in the gastric tissue, indomethacin weakens the gastric mucosa and causes gastric ulcer [10].

The main factors causing ulcer development and aggravation are ROS generation and oxidative stress. In this study, indomethacin-induced ulceration results in oxidative stress with decreased SOD activity and GSH levels and elevated levels of lipid peroxidation (MDA). The protective effects of SOD and GSH on the gastric mucosa against oxidative gastric mucosal injury by the extract are well recognized in the current study which supports similar findings of the extract and similar plant materials having remarkable anti-oxidant and anti-ulcerogenic activity [11,12].

Endogenous sulfhydryl (SH) has implications for gastroprotection since it is critical for preserving the health of the gastric mucosa and increasing the basal concentration of nonprotein sulfhydryl, which is primarily reduced GSH (-glutamyl-cysteinyl-glycine). MDA is a reliable indicator of mucosal damage brought on by ROS. A collection of metallo enzymes known as SOD catalyze the conversion of oxygen and hydrogen peroxide from superoxide radicals. The initial line of defense against ROS inside cells is SOD. Therefore, oxidative stress in the tissue can be reflected and shown by expression analysis using SOD immunohistochemistry and measuring GSH and MDA levels [13,14].

Furthermore, NSAIDs start the lipoperoxidation-producing ROS and operate as a prooxidant catalyst, which interferes with the antioxidant system of the mucosa's endogenous cells, causes leukocyte recruitment, and intensifies the inflammatory response.

Ulcer healing is a complicated process that includes anti-oxidant activation, cell migration,

proliferation, and replication of epithelial cells close to the edges to restore the glandular architecture, and granulation tissue angiogenesis at the ulcer's base [15,16].

In addition to lowering MDA levels, treatment with *U. aestuans* extract activated SOD expression and increased GSH levels in the gastric tissue.

The ulcerated area brought on by indomethacin was greatly reduced by the treatment with this plant in a dose-dependent manner, supporting the use of *U. aestuans* leaf extract by traditional medicine practitioners to stimulate gastrointestinal healing.

Histological examination of the lesion in the *U. aestuans* extract-treated groups' (Plates 4–6) reveals a reduction in the ulcerated region. On Plate 2, the stomach wall of the ulcerated control group can be seen to have significant erosive lesions. Additionally, in the group receiving standard medication treatment, restructuring of the epithelium together with healing of the ulcerated area may be seen both microscopically and histologically (Plate 3).

The main phyto-constituents and the identification mark for *U. aestuans* are thought to be phenolic compounds, tannins, and flavonones. Flavonoids and non-flavonoids are two different subclasses of phenolic compounds based on their chemical makeup. Anthocyanins, catechins, flavanones, flavones, flavonols, and isoflavones are among the polyphenols of the flavonoid type. Acids like hydroxycinnamic acid and phenolic acids are non-flavonoid types of polyphenols. The hydro-ethanolic leaf extract of *Urtica aestuans* was found to contain several phenolic compounds of pharmaceutical interest, including catechols like vanillin, ferulic acid, and salicin, flavonols like quercetin, gingerol, kaempferol, myricetin, and rutin, flavanones like naringenin, anthocyanidins like cyanidin, delphinidin, malvidin which is in line with previous report [17].

Reports on the potential health advantages of phenols have greatly grown in recent years [18].

According to reports, phenolic substances help treat stomach ulcers by promoting the production of PGE₂, mucus, and bicarbonate ions.

In another report, flavonoids work on the digestive system and possess antispasmodic,

anti-secretory, anti-diarrheal, anti-ulcer, and antioxidant activities. Among the cytoprotective substances for which anti-ulcerogenic activity has been thoroughly established are flavonoids [19].

Through a number of modes of action, including enhanced mucus production, antisecretory activity, free radical scavenging and antioxidant capabilities, and prevention of *Helicobacter pylori* growth, they defend the gastric mucosa against a variety of ulcerogenic substances [20,21].

Tannins prevent the onset of ulcers by precipitating proteins and restricting blood vessels. As shown by the gut secretions, their astringent activity can aid to precipitate microproteins on the ulcer site, generating an impenetrable coating over the lining, which prevents the development of an induced gastric ulcer in rats and shields the underlying mucosa from a decline in the ulcer scores [22].

These academic studies support the findings of the current study by showing that the phenolic compounds, flavonoids, and tannins found in *Urtica aestuans* leaves have a boosting influence on the defensive gastric factors and a debilitating effect on the offensive gastric factors.

Pharmacological research have documented and supported similar literature on plants having polyphenolic chemicals with substantial anti-ulcerogenic effect [23-25].

8. CONCLUSION

Preclinical tests using *U. aestuans* extract showed strong gastroprotective and anti-ulcer properties, respectively, which were meaningful pharmacological effects. The potential of the extract's phytochemicals to boost the antioxidant defense system and modulate inflammatory indicators may be the cause of these benefits. Overall, this research can help create a new phytotherapeutic therapy for peptic ulcer illness or serve as a new raw material for a functional food ingredient that can be added to food matrices.

CONSENT

It is not applicable.

ETHICAL APPROVAL

As per international standard or university standard written ethical approval has been collected and preserved by the author(s).

COMPETING INTERESTS

Authors have declared that no competing interests exist.

REFERENCES

1. Czekaj R, Majka J, Magierowska K, Sliwowski Z, Magierowski M, Pajdo R. Mechanisms of curcumin-induced gastroprotection against ethanol-induced gastric mucosal lesions. *J. Gastroenterol.* 2018;53:618–630.
2. Asali A, Alghamdi MA, Fallatah SA, Alholaily WA, Aldandan RG, Alnosair AH. Risk factors leading to peptic ulcer disease: systematic review in literature. *Int. J. Community Med. Public Health.* 2018;5:4617–4624.
3. Weltermann T, Schulz C, Macke L. Effect of frequently prescribed drugs on gastric cancer risk. *Best Pract. Res. Clin. Gastroenterol.* 2021;50-51.
4. Scally B, Emberson JR, Spata E, Reith C, Davies K, Halls H. Effects of gastroprotectant drugs for the prevention and treatment of peptic ulcer disease and its complications: a meta-analysis of randomised trials. *Lancet Gastroenterol Hepatol.* 2018;3(4):231–241.
5. Edilane Rodrigues Dantas De Araújo, Gerlane Coelho Bernardo Guerra, Anderson Wilbur Lopes Andrade, Júlia Morais Fernandes, Valéria Costa Da Silva, Emanuella De Aragão Tavares, Aurigena Antunes De Araújo, Raimundo Fernandes de Araújo Júnior, Silvana Maria Zucolotto. Gastric ulcer healing property of *Bryophyllum pinnatum* leaf extract in chronic model *In Vivo* and gastroprotective activity of its major flavonoid. *Front. Pharmacol.* 2021;744192.
6. Green I Kinikanwo, Charles C Nwafor, Weleh I lyke. Attenuation of reproductive dysfunctions by hydroethanolic leaf extract of *fleurya aestuans* in diabetic rats. *Asian Research Journal of Gynaecology and Obstetrics.* 2021;6(2): 24-31.
7. Sofowora A. Medicinal plants and traditional medicine in Africa. Ibadan, Nigeria. Spectrum Books Limited; 2008.
8. Kelly DA, Nelson R. Characterization and quantification by gas chromatography of flavonoids. *Journal of Braz Chemistry.* 2014;25.

9. Sayanti Bhattacharya SR, Chaudhuri S, Chattopadhyay, Bandyopadhyay SK. Healing properties of some Indian medicinal plants against indomethacin-induced gastric ulceration of rats. *Journal of Clinical Biochemistry and Nutrition*. 2007;41(2):106–114.
10. Lim JM, Song CH, Park SJ, Park DC, Jung GW, Cho HR. Protective effects of triple fermented barley extract (FBe) on indomethacin-induced gastric mucosal damage in rats. *BMC Complement. Altern. Med*. 2019;19:149.
11. Okereke SC, Elekwa I. Studies on the *In Vitro* antioxidant activity of *Fleurya Aestuans* leaf extract. *Journal of Environmental Science, Toxicology and Food Technology*. 2014; 8:33-41.
12. Tu PS, Tung YT, Lee WT, Yen GC. Protective effect of camellia oil (*Camellia Oleifera* Abel.) against ethanol-induced acute oxidative injury of the gastric mucosa in mice. *J. Agric. Food Chem*. 2017; 65:4932–4941.
13. Wang XY, Yin JY, Zhao MM, Liu SY, Nie SP, Xie MY. Gastroprotective activity of polysaccharide from *Hericium erinaceus* against ethanol-induced gastric mucosal lesion and pylorus ligation-induced gastric ulcer, and its antioxidant activities. *Carbohydr. Polym*. 2018;186(1):100–109.
14. Tu PS, Tung YT, Lee WT, Yen GC. Protective effect of camellia oil (*Camellia Oleifera* Abel.) against ethanol-induced acute oxidative injury of the gastric mucosa in mice. *J. Agric. Food Chem*. 2017;65:4932–4941.
15. Amang AP, Mezui C, Siwe GT, Emakoua J, Mbah G, Nkwengoua EZ. Healing and antisecretory effects of aqueous extract of *Eremomastax Speciosa* (Acanthaceae) on unhealed gastric ulcers. *Biomed. Res. Int*. 2017;1924320.
16. Kuna L, Jakab J, Smolic R, Raguz-Lucic N, Vcev A, Smolic M. Peptic ulcer disease: a brief review of conventional therapy and herbal treatment options. *J. Clin. Med*. 2019;8 (2):179.
17. Okereke Stanley C, Elekwa I, Chukwudoruo Chieme S. Preliminary phytochemical screening and gas chromatographic FID evaluation of *Fleurya Aestuans* leaf extracts. *International Journal of Current Biochemistry Research*. 2014; 2(3):37-43.
18. Shahidi F, Yeo J. Bioactivities of phenolics by focusing on suppression of chronic diseases: A review. *Int. J. Mol. Sci*. 2018;19:1573.
19. Glevitzky I, Dumitrel GA, Glevitzky M, Pasca B, Otrisal P, Bungau Cioca S. Statistical analysis of the relationship between antioxidant activity and the structure of flavonoid compounds. *Rev. Chim*. 2019;70 (9):3103–3107.
20. Justino J. Flavonoids - from biosynthesis to human health. *Intech Open*. 2021;4. DOI:10.5772/67810
21. Wang XX, Liu GY, Yang YF, Wu XW, Xu W, Yang XW. Intestinal absorption of triterpenoids and flavonoids from *Glycyrrhizae radix* et rhizoma in the human Caco-2 monolayer cell model. *Molecules*. 2017;22(10):1627.
22. De Moraes FP, Xiong J, Borges KC, Hoskin RT, Esposito D. Phytochemical content, antioxidant, anti-inflammatory activities and wound healing properties of freeze-dried fruits. *Act. Sci. Nutr. Health*. 2020;4(1):63–71.
23. Raeesi M, Eskandari-Roozbahani N, Shomali T. Gastro-protective effect of biebersteinia multifida root hydro-methanolic extract in rats with ethanol-induced peptic ulcer. *Avicenna J. Phytomed*. 2019;9(5):410–418.
24. Youn SH, Lim H, Ju Y, Soh JS, Park JW, Kang HS. Effect of gastroprotective agents on upper gastrointestinal bleeding in patients receiving direct oral anticoagulants. *Scand. J. Gastroenterol*. 2018;53 (12):1490–1495.
25. Akah PA, Onyirioha CA, Nworu CS, Ndu OO. Gastro-protective effects of the leaf extract, fractions and LD50 of *Fleurya aestuans* L (Urticaceae). *International Journal of Health Research*. 2009;2(1): 65-73.

© 2022 Charles et al.; This is an Open Access article distributed under the terms of the Creative Commons Attribution License (<http://creativecommons.org/licenses/by/4.0>), which permits unrestricted use, distribution, and reproduction in any medium, provided the original work is properly cited.

Peer-review history:

The peer review history for this paper can be accessed here:

<https://www.sdiarticle5.com/review-history/91698>