

---

## **Menetrier Disease: A Nephrotic Syndrome of the Stomach**

**Adedeji Okikiade <sup>a\*</sup>, Akinyode Esther <sup>a</sup>, Akoth Annah <sup>a</sup>, Ndu Franklin <sup>a</sup>,  
Olubunmi A. Olojede <sup>a</sup>, Edward Peter Taylor <sup>a</sup> and Oyewole Adijat <sup>a</sup>**

<sup>a</sup>All Saints University, College of Medicine, Saints Vincent and the Grenadines.

### **Authors' contributions**

*This work was carried out in collaboration among all authors. All authors read and approved the final manuscript.*

### **Article Information**

#### **Open Peer Review History:**

This journal follows the Advanced Open Peer Review policy. Identity of the Reviewers, Editor(s) and additional Reviewers, peer review comments, different versions of the manuscript, comments of the editors, etc are available here: <https://www.sdiarticle5.com/review-history/92093>

**Review Article**

**Received 02 August 2022  
Accepted 06 October 2022  
Published 14 October 2022**

---

### **ABSTRACT**

Menetrier Disease (MD) is a rare acquired disease that affects middle-aged men in their mid 40's and, to a lesser extent, women and children. Pierre Eugene Menetrier first described it. It is a premalignant disorder, sometimes associated with Helicobacter Pylori in adults, and Giardia lamblia and Cytomegalovirus in children. The enlargement of the rugae folds is due to increase production of transforming Growth Factor- $\alpha$  (TGF- $\alpha$ ) ligand, which subsequently activates epidermal growth factor receptor (EGFR) that stimulate the proliferation (hyperplasia) of the mucosal epithelium. Glandular dysfunction and protein leaks into the stomach result in anemia, hypoproteinemia, and edema. These are distinguishing characteristics of the pathology. Diagnosis is made by barium esophagogram, esophagogastroduodenoscopy (EGD), and serology. A monoclonal antibody called cetuximab (anti-EGFR) is the first treatment for Menetrier disease. Other supportive therapies are regimens for peptic ulcer disease, proton pump inhibitors, anticholinergic drugs, steroids, a high-protein diet, and gastrectomy. Prognosis is better for children than adults because of higher risk of developing gastric cancer. The review article aims to discuss this rare gastric mucosa (foveolar) disorder called Menetrier and support integration, research and learning among medical students and health professionals.

**Keywords:** Menetrier syndrome; hypertrophy of the stomach; H. pylori; EGFR; TGF- $\alpha$ .

## 1. INTRODUCTION

Menetrier disease (MD), also known as the nephrotic syndrome of the stomach, protein-losing gastropathy, or hypoproteinemic hypertrophic gastropathy. It is a rare acquired disease noted for the cerebriform-like enlargement of the rugae folds seen in the fundus and body of the stomach.

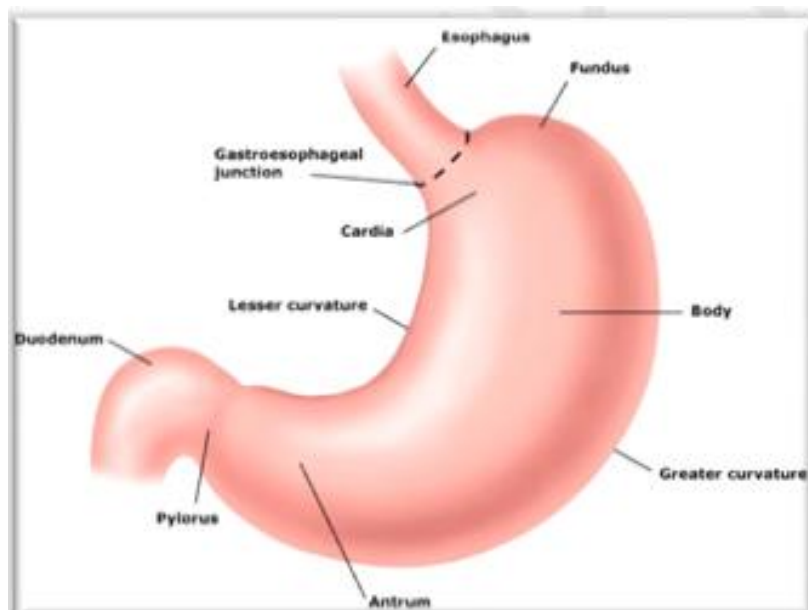
In 1888 the French surgeon, oncologist, and pathologist Pierre Eugene Menetrier first described a rare gastric disorder after a post-mortem study on cadavers [1]. The name Menetrier disease is sometimes used to describe any condition with large (hypertrophied) gastric folds. While some researchers believe that Menetrier disease and giant hypertrophic gastritis may be variants of the same disorder spectrum, a diagnosis of Menetrier is based on the presence of large gastric folds due to the overgrowth of mucous cells. \*There is little or no stomach inflammation, and Menetrier disease is a form of hyperplastic gastropathy [2].

It is associated with Giardiasis and Cytomegalovirus (CMV) infections in children, and the gram-negative curvilinear bacteria known as *Helicobacter Pylori* (*H. pylori*) in adults [1,3]. There is excessive production of transforming Growth Factor- $\alpha$  (TGF- $\alpha$ ), which activates EGFR leading to hyperplasia of the mucous forming foveolar glands. Mucus hypersecretion and excess protein leaks from the

bloodstream into the stomach are associated with malabsorption of nutrients, electrolytes, and vitamins and subsequently resulting in hypoproteinemia (protein losing gastropathy). The hyperplasia also leads to the atrophy of other glands, causing a decrease in the level of pepsinogen, hydrochloric acid, and Intrinsic factor. These morphological changes may result in anemia, generalized pitting edema, and gastric adenocarcinoma[3]. Diagnosis is usually by barium study, endoscopy with biopsy, and serology. Treatment recommendations are oral drugs for peptic ulcer disease, a high protein diet, chimeric monoclonal antibodies (Cetuximab), or, if necessary, gastrectomy. Prognosis is good for children, but it may lead to carcinoma or lymphoma in adults [4].

## 2. EPIDEMIOLOGY

Menetrier Disease is a rare disease affecting both children and adults. There has been difficulty estimating the prevalence of the disease because of challenges in diagnosis. However, less than 1000 cases are reported with slightly more males than females, particularly those between the ages of 30 and 60years[5]. A childhood form exists, and there have been reports of affected siblings suggesting a genetic involvement. There is also a variant linked with cytomegaly virus, accounting for 50-60 cases per year. The survival rate was 73% after five years and 65% after ten years [6].



**Fig. 1. The stomach**

Source: <http://getdrawings.com/image/human-stomach-drawing-56.jpg>

### 3. ETIOLOGY

The cause of Menetrier disease is not fully understood. It is believed to be an acquired disease rather than inherited[7,8]. There have been a few rare cases of siblings developing the disease, thought to be an autosomal dominant mode of inheritance. Many adult cases have been associated with the Helicobacter Pylori infection and children with the CMV Virus [7,9].H. pylori and CMV may not be the precursor agents of the disease process but a factor that contributes to the hyperplasia of the mucous forming foveolar glands, which increases the release of excessive Transforming Growth Factor- $\alpha$  (TGF- $\alpha$ ). H. pylori and CMV are not always observed [8].

### 4. PATHOPHYSIOLOGY

The Pathophysiology of Menetrier Disease is not fully understood, but some mouse models demonstrated that overexpressed TGF- $\alpha$  showed epithelial hyperplasia of the stomach. This overexpression of TGF- $\alpha$  produced characteristic presentations such as foveolar hyperplasia, glandular cystic dilatation, oxyntic atrophy, increased mucin production, and reduced acid secretion[9][15] [16].

Mouse studies have been conducted to explore the pathophysiology of Menetrier disease. These studies showed that hyperplasia of foveolar mucous cells is involved with upregulation in the epidermal growth factor receptor (EGFR) signaling. This subsequently leads to increased production of TGF- $\alpha$  by a factor of 1.5 to 2.1 times and in the growth of the gastric epithelial

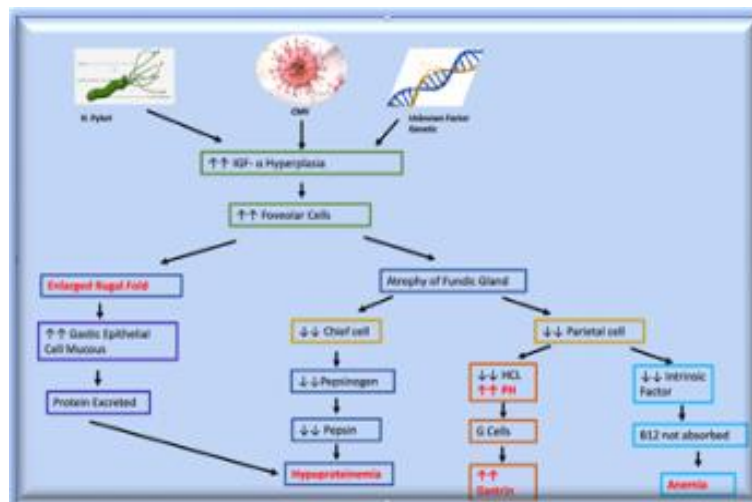
cells [9][14]. The overproduction of the mucosa presents as the large rugae folds. The proteinaceous mucous produced by these cells is increased, and the excess mucous is secreted into the lumen of the stomach and passed out with feces[10][14].

The excess TGF- $\alpha$  production and excess mucous production also lead to the atrophy of the chief and parietal cells. The chief cells are involved in the production of pepsinogen, so there is decreased pepsin with the atrophy of these cells. Pepsin is involved in the breakdown of proteins. The excretion of the excess mucous and the undigested proteins leads to severe Hypoproteinaemia[11,14].

The Parietal cells are involved in producing hydrochloric acid (HCl) and Intrinsic Factor (IF).In Menetrier disease, there is decreased HCl resulting in less availability of hydrogen ions (H<sup>+</sup>), thus activating G-cells to produce more gastrin from G cells(Fig. 2). The decrease acid may lead iron malabsorption causing iron deficiency anemia, but gastrin elevation is associated with gastric acid secretion and cancer growth.

There is depletion of intrinsic factor, a glycoprotein that binds vitamin B12 (cobalamin) and enables its absorption in the terminal ileum. Megaloblastic anemia can result from a cobalamin deficiency in this condition [12,15].

The protein-losing gastropathy can lead to hypoproteinemia, decreasing the oncotic plasma pressure and leading to pitting edema [13].



**Fig. 2. Pathophysiology flow chart of menetrier disease**  
 Source: [www.youtube.com](http://www.youtube.com), *Medicosis Perfectionalis*, 13 Aug. 2017

## 5. CLINICAL PRESENTATIONS

Typically, a patient would present with abdominal pain, nausea, protein-losing malnutrition, vomiting, diarrhea, abdominal pain, weight loss, and peripheral edema due to protein and albumin loss. In some cases, megaloblastic anemia may occur, characterized by symptomatology of anemia, neurological manifestations, and mild jaundice[13][16]. There is often a gradual onset of symptoms progressively worsening. There have been reports of abrupt onset and spontaneous remission, often associated with a cytomegalovirus (CMV) in children or a *Helicobacter pylori* infection in adults [14,15].

## 6. DIAGNOSIS

Menetrier disease can be accurately diagnosed using the following clinical histopathological procedures:

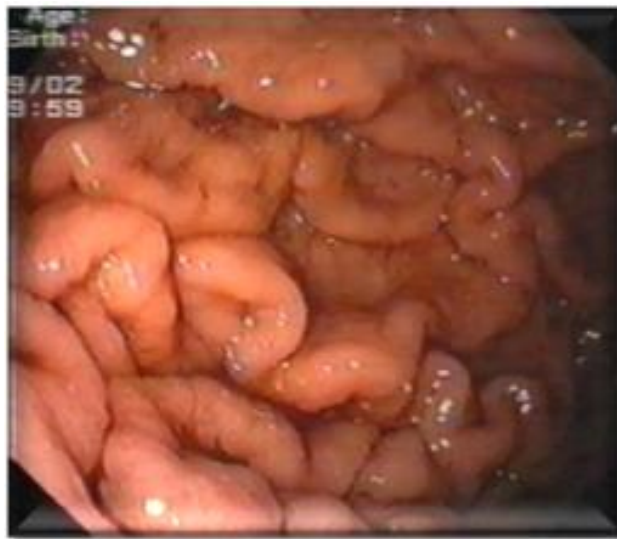- 1) **Endoscopic exams and Biopsy:** are used to examine the interior of the stomach. The pronounced large gastric folds in the gastric body will be observed [17]. The folds are not seen in the antrum. A histopathological study of a tissue sample obtained during the procedure is used to support the Diagnosis, but complications may be seen after biopsy especially in children [1,3].

The histology of Menetrier disease reveals foveal hyperplasia with corkscrew morphology and cystic dilated deep glands. Linear architecture is

maintained. A full-thickness mucosal biopsy will identify the deep glandular loss. There is a lack of inflammatory cells, intestinal metaplasia, or dysplasia. At times there is the presence of eosinophils, plasma cells, hyperplasia of smooth muscle, and edema. There is a loss of parietal cells due to atrophic oxyntic glands [1].

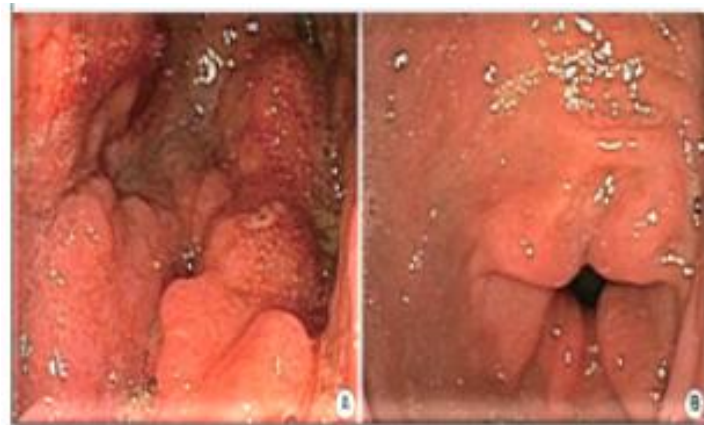
- 2) **Barium Meal:** The barium swallow reveals enlarged folds in the greater curvature of the stomach [17][18].
- 3) **Abdominal computed tomography(CT scan):** This reveals diffusely enlarged rugal folds that project into the lumen of the gastric fundus and body. The antrum is spared [15].
- 4) **Laboratory evaluations:** Include Polymerase chain reaction (PCR) confirming the presence of Cytomegalovirus (CMV) and *H. Pylori*. Other possible suggestive investigations are: [16,17]

- Complete blood count may showing Lymphopenia.
- Serum level of albumin reveals hypoalbuminemia and reduced globulin.
- Increased level of TGF- $\alpha$
- Gastric pH which increases to 4-7 (normal 1-3)
- Alpha-1-antitrypsin elevation.
- Elevated serum gastrin level.
- Megaloblastic anemia, but less often iron deficiency may be present.



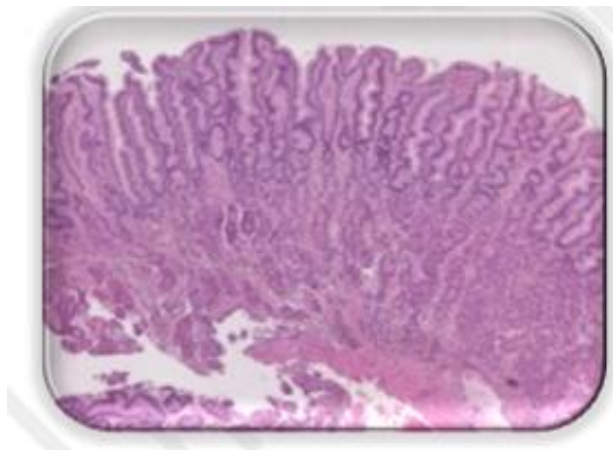
**Fig. 3. Giant Rugal folds as seen in an endoscope examination of the stomach**

Source: Medbulletins



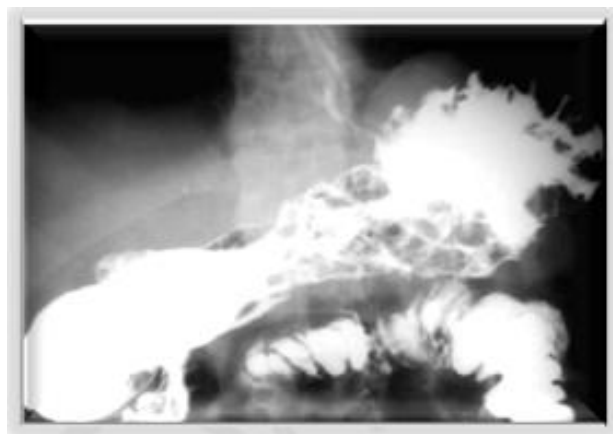
**Fig. 4. Endoscopic appearance of Menetrier Disease (A) Gastric body of Menetrier Disease patient with diffuse hypertrophic gastric folds. (B) The gastric antrum of the same patient is not involved**

*Source: Ménétrier's Disease: Its Mimickers and Pathogenesis - PMC (nih.gov)*



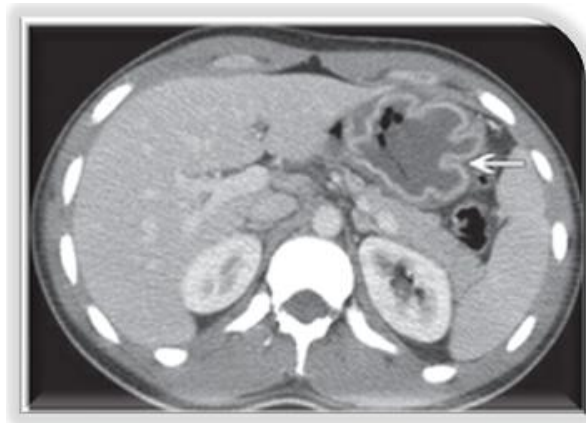**Fig. 5. Foveolar hyperplasia with corkscrew morphology and dilated deep glands - Pathol Transl Med. 2016**

*Source: Ménétrier's Disease: Its Mimickers and Pathogenesis - PMC (nih.gov)*



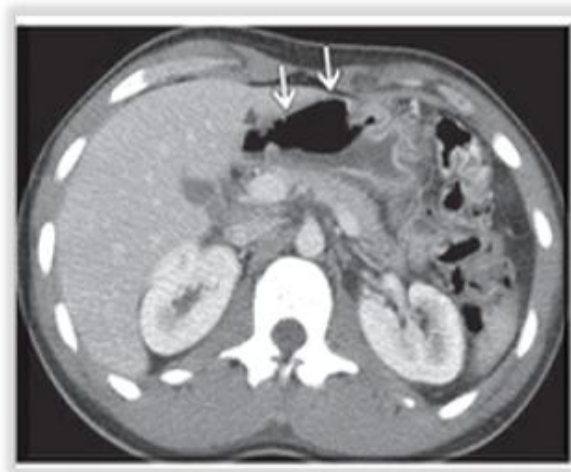
**Fig. 6. Barium swallow revealing enlarged folds along greater curvature in the stomach – Rev Assoc Med Bras 2017**

*Source: Ménétrier's Disease: Its Mimickers and Pathogenesis - PMC (nih.gov)*



**Fig. 7. Axial contrast material-enhanced CT image at the level of the gastric fundus shows gastric wall thickening and enhancement (arrow)**

*Source: Radiographics (2009).*



**Fig. 8. Axial contrast-enhanced CT image of the distal stomach reveals that the body is primarily involved, and the antrum is relatively spared (arrows)**

*Source: Radiographics (2009).*

A flow chart outlining the diagnosis decision-making steps for Menetrier Disease in Fig. 9.

## 7. ASSOCIATED DISEASES

Menetrier Disease may be associated with other unrelated diseases, and that may cause variation in its clinical manifestations.

Cases with autoimmune diseases such as inflammatory bowel disease, sclerosing cholangitis, and ankylosing have been reported in Menetrier Disease[18].

There is an increased risk of gastric cancer, and 8.9% of patients developed gastric cancer after 10 years of follow-up [19,20].

## 8. DIFFERENTIALS

Diseases that present with thickened gastric folds must be differentiated from Menetrier. The correlation of histological findings with clinical features is important in establishing an accurate diagnosis [1][21][22].

**Zollinger-Ellison syndrome** - peptic ulcers in the GI tract and parietal cell hyperplasia [22][23].

***H. pylori* gastritis** - Gastritis is present with a positive *H. pylori* test. Gastritis is not found in Menetrier Disease [22].

**Hypertrophic lymphocytic gastritis** - presents with severe inflammation with predominant intraepithelial lymphocytes[22][24].

**Gastric polyps** - more focal and can be numerous, mimicking Menetrier disease [22].

**Gastric adenocarcinoma** - dysplasia and loss of structure differentiate this from Menetrier syndrome [20][22].

Other infectious conditions like histoplasmosis, syphilis, tuberculosis and infiltrative disorders such as sarcoidosis can also present similar to Menetrier disease [20,22]. It is, therefore, imperative to rule out some of these conditions in some cases (Table 1) [22].

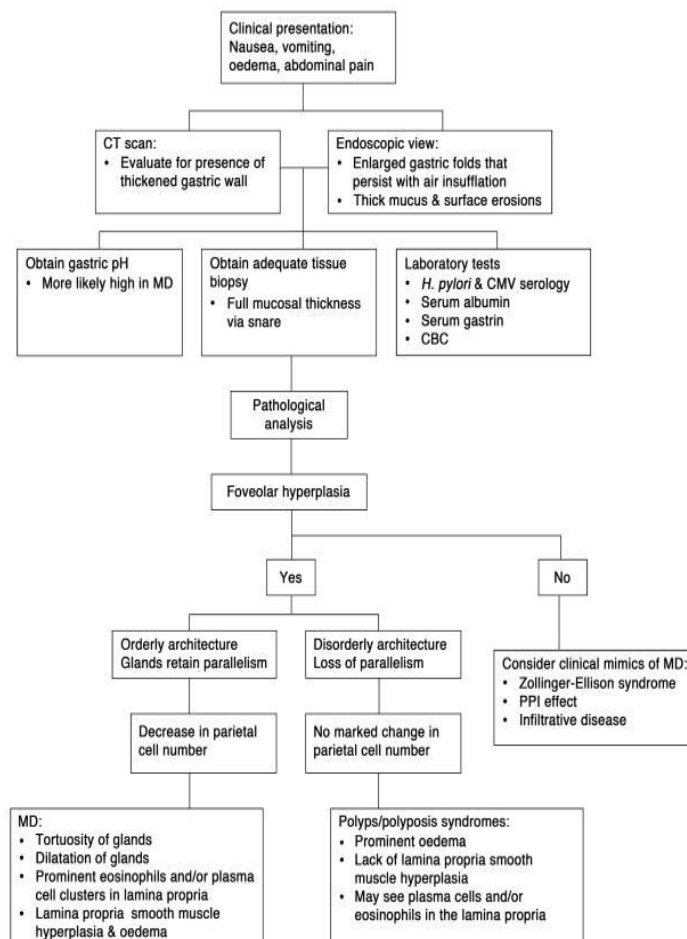
### 9. MANAGEMENT

Treatment of Menetrier disease may be spontaneous or remission with the use of medications, intravenous protein and albumin, blood transfusions, and surgery[21][28] [29].

Cases that have tested positive for H. Pylori or CMV infections are treated with respective antibiotics, proton-pump inhibitors and antiviral medications first [22][25][28].

A high protein diet is recommended. If necessary, intravenous protein, albumin, and blood transfusions are used for malnourished or anemic cases [23]. In most cases, children who have had a CMV infection fully recovered after treatment for the virus, along with appropriate protein and anemia treatment [24][25].

An anti-cancer drug Cetuximab (Erbix), given intravenously, has been shown to reduce the thickness of the stomach wall from the overgrowth of mucous cells by blocking the activity of epidermal growth factor (TGF- $\alpha$ ) and significantly improving symptoms[1][26] [27]. Patients must be monitored carefully for side effects. This is the first-line treatment for MD[5,1].



**Fig. 9. Clinicopathological decision-making tree for the Diagnosis of Menetrier Disease - "Distinguishing Menetrier's Disease from Its Mimics" Gut Oct. 2010 –**  
 Source:[https://www.researchgate.net/publication/316705109\\_Severe\\_hypoproteinemia\\_as\\_a\\_harbinger\\_of\\_Menetrier%27s\\_disease\\_in\\_autoimmune\\_pancreatitis](https://www.researchgate.net/publication/316705109_Severe_hypoproteinemia_as_a_harbinger_of_Menetrier%27s_disease_in_autoimmune_pancreatitis)

**Table 1. Differential diagnosis of Menetrier Disease Source: Journal of Pathology and Translational Medicine 2015**

<b>Diagnosis</b>	<b>Distribution</b>	<b>Location in stomach</b>	<b>Hyperplastic mucosal compartment</b>	<b>Pathologic features.</b>
Menetrier's disease	diffuse	Body and fundus; relatively sparing of antrum	Foveolar epithelium	Massive foveolar hyperplasia.
Hypertrophic lymphocytic gastritis	Diffuse	Body and fundus; relatively sparing of antrum	Foveolar epithelium	Prominent intraepithelial lymphocytes
Hypertrophic hypersecretory gastropathy	diffuse	Body and fundus: atrophic antrum.	All layers	Hyperplasia of all glandular compartments.
Zollinger Ellison syndrome	diffuse	Body and fundus	Parietal cells	Parietal cell hyperplasia
Hyperplastic polyp	focal	Antrum, body and fundus are also possible.	Foveolar epithelium	Foveolar hyperplasia with architectural distortion.
Polyposis syndrome with hamartomatous polyps.	variable	Body, fundus and antrum	Foveolar epithelium	Features similar to hyperplastic polyp.
Gastric adenocarcinoma and proximal polyposis of the stomach	Variable	Body and fundus.	Oxyntic glands	Fundic gland polyps with low and high grade dysplasia
Diffuse gastric carcinoma	variable	Body, fundus and antrum	Not applicable	Infiltrating carcinoma, diffuse type.
Lymphoma	variable	Body, fundus and antrum	Not applicable	Effacement of gastric mucosa by infiltrating lymphoma cells.
Amyloidosis	variable	Body, fundus and antrum	Not applicable	Acellular, amorphous eosinophilic material surrounding glands.

Source: *Ménétrier's Disease: Its Mimickers and Pathogenesis - PMC (nih.gov)*



Oral medications like proton pump inhibitors for peptic ulcer disease and metoclopramide for controlling nausea, vomiting, and abdominal pain may also be prescribed [2][28][29].

Gastrectomy may be required to remove a part or all of the stomach in severe cases or index of suspicion of malignant transformation [26].

## 10. CONCLUSION

Menetrier disease is associated with excessive TNF alpha in the gastrointestinal tract, causing foveolar surface mucus cell hyperplasia and increased epidermal growth factor receptor (EGFR) signaling [27]. This disease is also known as the nephrotic syndrome of the stomach, protein-losing gastropathy, or hypoproteinemic hypertrophic gastropathy [23]. It may be due to exposure to CMV in children or H. Pylori in adults. It is seen slightly more in middle-aged men than women [25].

Menetrier Disease's hallmark is the cerebrum enlargement of rugal folds in the stomach, mainly affecting the fundus and body [7]. This hyperplasia causes atrophy of the chief and parietal cells, affecting protein metabolism and leading to protein-losing gastroenteropathy. Another complication of Menetrier disease is anemia. Hyperplasia is also associated with an increase in the risk of adenocarcinoma [7] [26]. Diagnosis of the disease has been made using x-ray barium studies, biopsy, and serology [1][17][18]. Treatment aims to eliminate H. pylori, treat with ganciclovir, cetuximab, a high protein diet, or oral drugs used for Peptic ulcer disease [25][27][29][30]. Gastrectomy is used if the former treatments are not effective [26][30]. The prognosis for children is good as the disease is self-limiting, while it may lead to primary gastric carcinoma or lymphoma in adults [3][26].

## CONSENT

It is not applicable.

## ETHICAL APPROVAL

It is not applicable.

## COMPETING INTERESTS

Authors have declared that no competing interests exist.

## REFERENCES

1. Menetrier, Pierre. In: Archives de physiologie normale et pathologique. 1888(1):32-55.
2. Feldman, Mark, and William O. Tschumy Jr. "Menetrier Disease." NORD (National Organization for Rare Disorders). (Latest version, 2017). Available: <https://rarediseases.org/rare-diseases/menetrier-disease/>
3. Pesce F, Barabino A, Dufour C, Caffarena PE, Callea F, Gatti R. J Pediatr Gastroenterol Nutr. 1992;14:323-6.
4. Xiong, LI-Shou, and Ying-Ying Gong. Natural History of Adult-Onset Ménétrier's Disease: Report of a Case with 9-Year Follow-Up. Experimental and Therapeutic Medicine. 2016;11(6):2462–2466. DOI: 10.3892/etm.2016.3181.
5. Gore, Meghana, et al. "Menetrier Disease." *PubMed*, StatPearls Publishing; 2022.
6. Coffey RJ, Tanksley J. Pierre Ménétrier and his disease. Trans Am Clin Climatol Assoc. 2012;123:126-33.
7. Suter WR, Neuweiler J, Borovicka J, Binek J, Fantin AC, Meyenberger C. Cytomegalovirus-induced transient protein-losing hypertrophic gastropathy in an immunocompetent adult. Digestion. 2000; 62:276–9.
8. Bluth RF, Carpenter HA, Pittelkow MR, Page DL, Coffey RJ. Immunolocalization of transforming growth factor-alpha in normal and diseased human gastric mucosa. Hum Pathol. 1995; 26(12):1333-1340. DOI: 10.1016/0046-8177(95)90298-8
9. Xiong, LI-Shou, and Ying-Ying Gong. "Natural History of Adult-Onset Ménétrier's Disease: Report of a Case with 9-Year Follow-Up." Experimental and Therapeutic Medicine. 2016;11(6):2462–2466. DOI: 3892/etm.2016.3181.
10. Dempsey PJ, Goldenring JR, Soroka CJ, et al. Possible role of transforming growth factor alpha in the pathogenesis of Ménétrier's disease: Supportive evidence from humans and transgenic mice. Gastroenterology 1992;103:1950–63.
11. Tan DT, Stempien SJ, Dagradi AE. "The clinical spectrum of hypertrophic hypersecretory gastropathy. Report of 50 patients". Gastrointest. Endosc. 1971; 18(2):69–73. .
12. Krikilion, Jasmina, et al. "Diagnosis and Management of Ménétrier Disease in Children: A Case Series Review." Pediatric

- Gastroenterology, Hepatology & Nutrition. 2021;24(1):109, DOI: 10.5223/pghn.2021.24.1.109.
13. Rodriguez, Nicole M, and Karen Shackelford. "Pernicious Anemia." Nih.gov, StatPearls Publishing, 10 Apr. 2019,
  14. "Ménétrier's Disease Pathophysiology." *Www.youtube.com*, Medicosis Perfectionalis, 13 Aug. 2017, [www.youtube.com/watch?v=qblOVt-4WsM](http://www.youtube.com/watch?v=qblOVt-4WsM). Accessed 2 Aug. 2022.
  15. Adapted from "Ménétrier's Disease Pathophysiology." *Www.youtube.com*, Medicosis Perfectionalis, 13 Aug. 2017, [www.youtube.com/watch?v=qblOVt-4WsM](http://www.youtube.com/watch?v=qblOVt-4WsM). Accessed 2 Aug. 2022.
  16. Setakhr V, Muller G, Hoang P, Lambert AS, Geubel A. Cytomegalovirus associated protein losing gastropathy in an immunocompetent adult: a case report. *Acta Gastroenterol Belg*. 2007; 70:296–9.
  17. Smith, Robert. "Menetrier Disease - Gastrointestinal - Medbullets Step 1." *Step1.Medbullets.com*, [step1.medbullets.com/gastrointestinal/110041/menetrier-disease](http://step1.medbullets.com/gastrointestinal/110041/menetrier-disease).
  18. Eisenstat DD, Griffiths AM, Cutz E, Petric M, Drumm B. Acute cytomegalovirus infection in a child with Ménétrier's disease. *Gastroenterology*. 1995; 109:592–5.
  19. Wolfsen HC, Carpenter HA, Talley NJ. Ménétrier's disease: A form of hypertrophic gastropathy or gastritis? *Gastroenterology*. 1993; 104:1310–9.
  20. Chebli JMF, Chebli LA, Ribeiro TCDR, Gaburri PD. Severe hypoproteinemia as a harbinger of Ménétrier's disease in autoimmune pancreatitis; 2017.
  21. Friedman, Joseph, et al. "Ménétrier Disease." *Radio Graphics*. 2009;29(1): 297–301. DOI: 10.1148/rg.291075216.
  22. Rich A, Toro TZ, Tanksley J, et al. Distinguishing Ménétrier's disease from its mimics. *Gut*. 2010;59:1617–24].
  23. Sisson G, Harris AW. Ménétrier's disease. *Gut*. 2007;56(1):156.
  24. Distinguishing Ménétrier's Disease from Its Mimics. *Gut*. 2010;59(12):1617–1624. DOI: 10.1136/gut.2010.220061.- Table used with permission
  25. Xiao SY, Hart J. Marked gastric foveolar hyperplasia associated with active cytomegalovirus infection. *Am J Gastroenterol*. 2001;96:223–6.
  26. Almazar AE, Penfield JD, Saito YA, Talley NJ. Survival Times of Patients with Menetrier's Disease and Risk of Gastric Cancer. *Clin Gastroenterol Hepatol*. 2021; 19(4):707-712.
  27. Takagi H, Fukusato T, Kawaharada U, Kuboyama S, Merlino G, Tsutsumi Y. Histochemical analysis of hyperplastic stomach of TGF-alpha transgenic mice. *Dig Dis Sci*. 1997;42:91–8.
  28. Frederiksen HJ, Olsen N, Krag E. Cimetidine treatment of Menetrier's syndrome. *Ugeskr Laeger*. 1978;140:298–9.
  29. Krol TC, Isenberg JI. Remission in a patient with Menetrier's disease: spontaneous or induced by treatment? *J. Clin Gastroenterol*. 1985;7:161–8.
  30. Fiske, William H., et al. "Efficacy of Cetuximab in the Treatment of Ménétrier's Disease." *Science Translational Medicine*. 2009;1(8). [www.ncbi.nlm.nih.gov/pmc/articles/PMC3638759/](http://www.ncbi.nlm.nih.gov/pmc/articles/PMC3638759/), 10.1126/scitranslmed.3000320. Accessed 29 July 2022.

© 2022 Okikiade et al.; This is an Open Access article distributed under the terms of the Creative Commons Attribution License (<http://creativecommons.org/licenses/by/4.0>), which permits unrestricted use, distribution, and reproduction in any medium, provided the original work is properly cited.

Peer-review history:  
The peer review history for this paper can be accessed here:  
<https://www.sdiarticle5.com/review-history/92093>