



Clinical Outcome of Ventricular Septal Rupture Complicating Acute Myocardial Infarction – A Single Centre Retrospective Study

**Jayanty Venkata Balasubramaniyan^{1*}, Ravanasamudram Hariharan Lakshmi²,
Harsimran Singh¹, J. S. Sathyanarayana Murthy¹
and Vaishnavi Chandrakumar¹**

¹Sri Ramachandra Institute of Higher Education and Research Porur ; Chennai 600 116, India.

²Hariharan Diabetes and Heart Care Hospitals; Chennai, India.

Authors' contributions

This work was carried out in collaboration among all authors. All authors read and approved the final manuscript.

Article Information

DOI: 10.9734/JPRI/2021/v33i43B32544

Editor(s):

(1) Dr. Rafik Karaman, Al-Quds University, Palestine.

Reviewers:

(1) Ltaief Zied, Lausanne University, Switzerland.

(2) Liao, NTU, Singapore.

Complete Peer review History: <https://www.sdiarticle4.com/review-history/72154>

Original Research Article

Received 29 June 2021

Accepted 09 September 2021

Published 10 September 2021

ABSTRACT

Objective: Ventricular Septal Rupture (VSR) following Acute Myocardial Infarction (AMI) is a fatal mechanical complication with high incidence of mortality. The aim of this study is to explore the clinical outcomes and to identify the factors related to early mortality in patients with VSR after AMI.

Materials and Methods: This was a retrospective study and we collected clinical data of 21 adult patients with VSR following AMI from April 2012 and October 2020 who got admitted at our tertiary care centre. The patients were classified into two groups. The first group consisted of patients who died within two weeks from the diagnosis of VSR following AMI and the second group comprised of patients who survived more than two weeks after VSR.

Results: A total of 21 patients (mean age of 66.19±9.47 years) were enrolled in this study. The most common MI was Anterior MI (71.4%) and the location of VSR was predominantly in the anterior and apical septum (76.2%). The overall early mortality was 85.9% (n=18). 80.95% (n=17) of patients died within two weeks of diagnosis of AMI. Of the 4 patients who survived more than two weeks, three patients survived. The operative mortality in our study was 47%.

Conclusion: The prognosis for VSR in AMI remains poor. Renal failure is accompanied with high rate of early mortality in patients with VSR complicating AMI. History of smoking is associated with poor outcome.

Keywords: Ventricular septal rupture; acute myocardial infarction; mortality; surgical repair.

ABBREVIATIONS

VSR : Ventricular Septal Rupture

AMI : Acute Myocardial Infarction

1. INTRODUCTION

Ventricular Septal Rupture (VSR) is an exceedingly rare complication following Acute Myocardial Infarction (AMI) associated with high mortality [1-4]. Before the introduction of thrombolytic therapy, the occurrence of VSR was around 1-3% and the mortality was high as 90% in medically managed patients compared to 45% in surgically treated patients [2,4-5]. After the advent of thrombolytic therapy, the occurrence of VSR was reported to be 0.31% [1]. With the introduction of primary Percutaneous Coronary Intervention (PCI), the incidence of VSR reduced to 0.23-0.71% [6-8]. Despite the recent reperfusion therapies, the management of VSR in AMI patients still remains a challenge. The GUSTO-I (The Global Use of Strategies to Open Occluded Coronary Arteries) trial and the SHOCK (Should We Emergently Revascularize Occluded Coronaries for Cardiogenic Shock) registry for in-hospital death have reported that the mortality rate for VSR in AMI patients remains elevated [1,9].

Surgical repair may be required urgently, but there is no consensus on the optimal timing for surgery [10]. Early surgery is associated with a high mortality rate, reported as 20–40%, and a high risk of recurrent ventricular rupture, while delayed surgery allows easier septal repair in scarring tissue but carries the risk of rupture extension and death while waiting for surgery. For this reason, early surgery should be performed in all patients with severe heart failure that does not respond rapidly to aggressive therapy, but delayed elective surgical repair may be considered in patients who respond well to aggressive heart failure therapy. Percutaneous closure of the defect with appropriately designed devices may soon become an alternative to surgery [11].

Studies have demonstrated better outcomes with the utilization of transcatheter closure of VSR,

however mortality remains high especially in patients with Cardiogenic shock [11-14]. Available data suggest that use of surgical modality had significantly beneficial outcomes, however operative mortality remains high with deteriorated hemodynamic status [25-17]. Nevertheless, published data revealed likelihood of residual shunts flowing the concomitant use of transcatheter device closure [11,18-19]. Furthermore, a residual shunt of upto 40% was reported post device closure and eventually requiring surgical closure [20]. However published data on the time frame for closure of VSR following MI is limited. It is concerning that the mortality associated with VSR complicating AMI remains unchanged over the past two decades despite newer treatment modalities [21]. The aim of this study is to explore the patient's clinical profile and to study the factors associated with mortality of patients with VSR following AMI.

2. MATERIALS AND METHODS

2.1 Study Population and Study Design

This was a retrospective study and we collected clinical data of 35 adult patients with VSR following AMI from April 2012 and February 2020. In this study, we included 21 patients with post MI VSR who primarily got admitted in our tertiary care centre and also patients who were referred from other hospitals. We excluded patients associated with any Congenital Heart Disease and we did not enrol patients who died at the initial presentation. Demographic details, past medical history, LVEF, location/size of VSR, use of IABP, details of medical treatment and surgical details were collected. The patients were categorized into two groups. The first group comprised of patients on early phase survivors (survived more than two weeks from the diagnosis of VSR) and the second group consisted of patients who died within two weeks of diagnosis of VSR following AMI. The decision on surgery was decided by the cardiac team. As per our hospital protocol patients who respond to aggressive medical treatment (including IABP) are kept on aggressive medical treatment and later planned for surgery, but those patients who does not respond to medical treatment are

planned for emergency surgery after explaining the grave prognosis and taking the consent from the family. AMI definition was made in concordance with the definition of myocardial infarction from the Fourth Universal Definition of Myocardial Infarction. Patients in the survival group were followed up by telephonic calls or during clinical visit.

2.2 Statistical Analysis

All data were entered in Microsoft Excel and analysis was performed using SPSS version 22 (Statistical Package for Social Sciences, Chicago, IL, USA). The quantitative variables were describes as frequency and percentages and were analyzed using Chi-square test or Fischer's exact test. Qualitative variables were summarized as mean standard deviation and difference in mean was analyzed using Student t-test. Univariate and multivariate logistic regression tests were performed to determine the factors for mortality among the patients.

3. RESULTS

3.1 Incidence

From 2012 to 2020, 10,184 patients with AMI presented at our centre. Among them, 35 (0.34%) patients had AMI complicated with VSR.

3.2 Patient Characteristics

The patients' baseline characteristics are presented in Table 1. In our study, the average age of patients were 66.19±9.47 years old (from 45 to 78 years) and men contributed to 71.42% of the study population. Most of the patients had one or combined co-morbidities of which

diabetes (52.4%) was the most common followed by hypertension (28.6%). A higher proportion of patients had Anterior MI (71.4%) in this study. Similarly Anterior/apical septum (76.2%) was the most common location of VSR whereas the inferior/posterior septal VSR was found among 28.6% the patients. Not all the patients were treated with thrombolytic therapy or PCI and Coronary artery revascularization surgery. The mean duration from the onset of angina to presentation at our tertiary care centre was 1.07±0.917 days and Fig. 1 illustrates the days taken to reach hospital for diagnosis and treatment of Acute Myocardial Infarction. Majority of patients (57.1%) required IABP support.

Table 1. Baseline characteristics of patients with VSR following AMI

| Characteristics | Mean±SD or N(%) |
|------------------------------------|-----------------|
| Age (years) | 66.19±9.47 |
| Sex Male | 15(71.4) |
| Female | 6(28.6) |
| Diabetes Mellitus | 11(52.4) |
| Hypertension | 6(28.6) |
| History of Angina | 20(95.2) |
| History of Smoking (Current/Prior) | 20(95.2) |
| Renal Failure (Acute/Chronic) | 14(66.7) |
| MI Location Anterior MI | 15(71.4) |
| Non Anterior MI | 6(28.6) |
| IABP | 12(57.1) |
| LVEF (%) | 43.48±9.53 |
| VSR size(mm) | 12.97±4.97 |
| VSR Location Anterior/Apical | 16(76.2) |
| Inferior/Posterior | 5(23.8) |
| Concomitant CABG surgery | 7(33.3) |

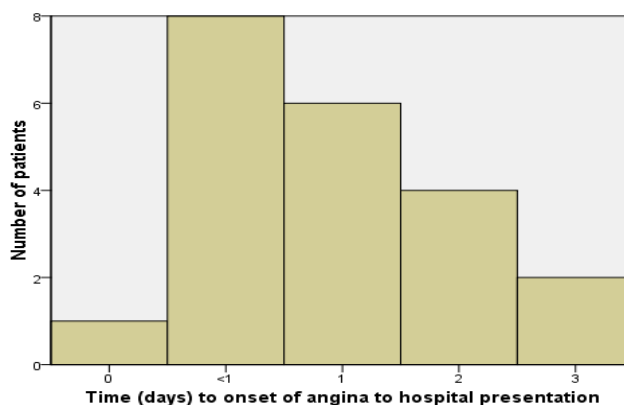


Fig. 1. Time taken from the onset of angina to hospital presentation for diagnosis of Acute Myocardial Infarction

3.3 Clinical Outcome

In our study, we observed that there was no difference in age in both the groups (Table 2). All the patients who had VSR following AMI and died within < 2 weeks presented with angina ($p=0.035$) and had greater size of VSR when compared to the survivor group. All the patients in the non-survivor group had either past or present history of smoking ($p=0.035$). Majority of patients (76.4%) had history of renal failure (either acute or chronic) in the preoperative period among the non-survivor group ($p=0.049$) while 50% of patients had renal failure in the survivor group. Use of IABP was observed in both the groups.

Anterior MI territory was the most commonly involved territory among both the groups but there was no statistical significance present. In this study, the survivor group had a smaller VSR defect size and a slightly higher LVEF, nevertheless there was no statistical significance. Of the four patients who survived more than two weeks period, two patients underwent CABG and VSR repair, one patient underwent VSR repair whereas one did not undergo immediate surgery or percutaneous intervention for VSR due to deranged renal parameters. However, one patient who underwent CABG and VSR repair died on the 15th day from the day of diagnosis of AMI. The other three patients were discharged and followed up. Due to small study sample size, multivariate logistic regression did not yield any results.

4. DISCUSSION

VSR following Acute Myocardial Infarction is a serious complication. In our study, we have observed the incidence of VSR post AMI to be 0.34%, similar to the reports from the GUSTO I trial [1]. The overall in-hospital mortality was 85.7%, similar to study conducted by Menon et al. [9] Our study revealed that 80.95% of patients died within two weeks of diagnosis of AMI and VSR despite aggressive medical management/surgical intervention and/or IABP support. The operative mortality in our study was 47% and this was in concordance with previous studies [16,22–24]. Study done by Fishbein et al revealed that connective tissue proliferation was not present until third week post infarction [25]. Moreover, it would not be ideal to wait for three weeks for surgery due to complications such as Congestive heart failure and multi organ failure. The mortality with medical management for VSR in AMI is higher than the mortality from surgical treatment.

In this study, 47.6% ($n=10$) of patients did not undergo surgery or percutaneous intervention due to hemodynamic instability, unsuitable anatomy and deranged renal parameters. There were managed medically and hemodynamic unstable patients were planned for surgery after stabilization with circulatory support. Among the 10 patients, one patient was discharged and the remaining nine patients succumbed to death. The ideal therapeutic management and timing for VSR repair still remains controversial.

Table 2. Comparison of patients profile between early phase non-survivor and early phase survivor group

| Parameters | Early phase non-survivor (n=17) | Early phase survivor (n=4) | p Value |
|--------------------------|---------------------------------|----------------------------|---------|
| Age (years) | 66.24±9.3 | 66±11.69 | .966 |
| Male sex | 13(76.47) | 2(50) | .292 |
| Diabetes Mellitus | 8(47) | 3(75) | .314 |
| Hypertension | 5(29.4) | 1(25) | .861 |
| History of Angina | 17(100) | 3(75) | .035 |
| History of Smoking | 17(100) | 3(75) | .035 |
| Renal Failure | 13(76.47) | 1(25) | .049 |
| MI Classification | | | .861 |
| Anterior MI | 12(70.5) | 3(75) | |
| Non Anterior MI | 5(29.4) | 1(25) | |
| IABP | 10(58.8) | 2(50) | .748 |
| LVEF (%) | 43.06±10 | 45.25±7.6 | .690 |
| VSR size(mm) | 13.85±4.8 | 9.2±4.1 | .096 |
| Concomitant CABG surgery | 5(29.4) | 2(50) | .432 |

Data are presented as n(%) or mean±(sd). CAD, Coronary Artery Disease; LVEF, Left Ventricular Ejection Fraction; IABP, Intra Aortic Balloon Pump; VSR, Ventricular Septal Rupture

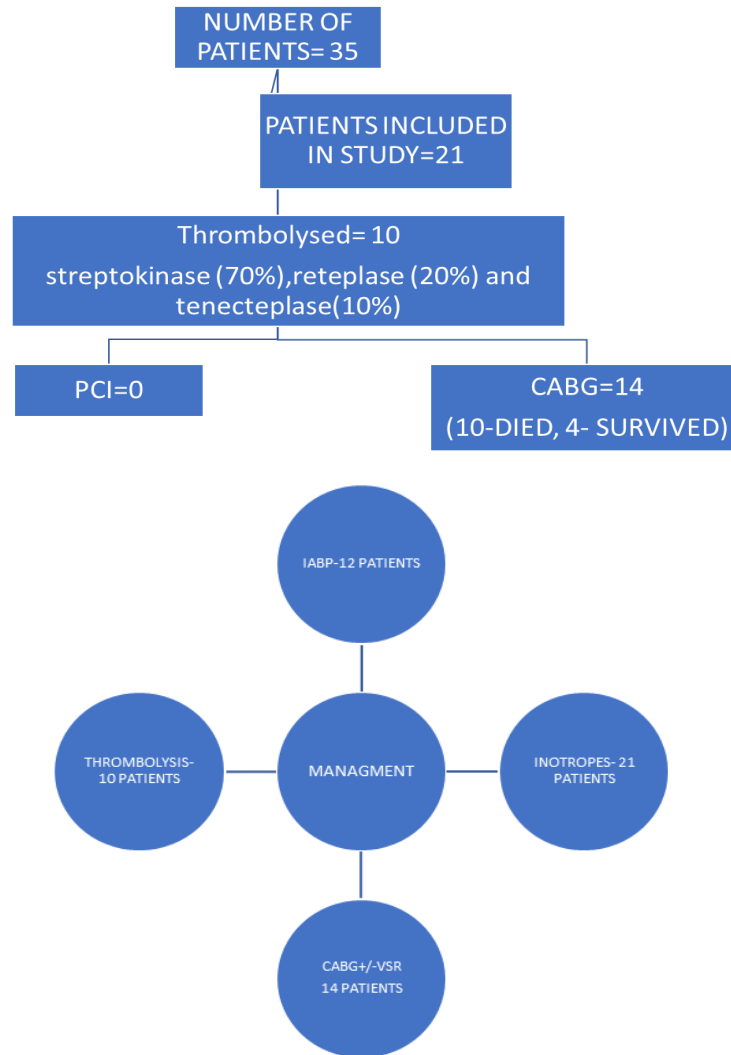


Fig. 2. Flow chart of Patient's characteristic with details on treatment: number of patient: thrombolysis, PCI and surgery, and outcome

In a previous study [26] presence of angina was found to be higher in acute phase survivor of VSR following AMI. However, in our study revealed that 95.2% (n=20) of patients had presented with history of angina with higher predominance in the non-survivor group had angina. Similarly, 95.2% (n=20) patients had history of smoking (either past or present) and majority of them belonged to the non-survivor group. Studies have demonstrated that smoking had been linked to poor outcome with Coronary Artery Disease [27-28].

5. CONCLUSION

The mortality for VSR following AMI was as high as 52.9% on medical management and the

operative mortality was 47% despite surgical intervention. The overall prognosis for VSR in AMI remains poor. Advanced surgical techniques over the recent years have resulted in improved prognosis. Renal failure in the preoperative period predominantly associated with early mortality in patients with VSR complicating AMI. Our study also revealed that smoking as an important factor associated with poor prognosis in patients having AMI complicated with VSR.

LIMITATION

Our study had many limitations. This is a retrospective and a single centre study. Due to relatively infrequent incidence of VSR following AMI, the study population size was small to detect

any statistical significance and could have also restricted the number of statistically significant variables.

CONSENT AND ETHICAL APPROVAL

As per international standard or university standard guideline Patient's consent and ethical approval has been collected and preserved by the authors.

COMPETING INTERESTS

Authors have declared that no competing interests exist.

REFERENCES

1. Crenshaw BS, Granger CB, Birnbaum Y, Pieper KS, Morris DC, Kleiman NS et al. Risk factors, angiographic patterns, and outcomes in patients with ventricular septal defect complicating acute myocardial infarction. *Circulation*. 2000;101(1):27–32.
2. Birnbaum Y, Fishbein MC, Blanche C, Siegel RJ. Ventricular Septal Rupture after Acute Myocardial Infarction. *N Engl J Med*. 2002;347(18):1426–32.
3. Poulsen SH, Præsthholm M, Munk K, Wierup P, Egeblad H, Nielsen-Kudsk JE. Ventricular Septal Rupture Complicating Acute Myocardial Infarction: Clinical Characteristics and Contemporary Outcome. *Ann Thorac Surg*. 2008;85(5):1591–6.
4. Pohjola-Sintonen S, Muller JE, Stone PH, Willich SN, Antman EM, Davis VG et al. Ventricular septal and free wall rupture complicating acute myocardial infarction: Experience in the Multicenter Investigation of Limitation of Infarct Size. *Am Heart J*. 1989;117(4):809–18.
5. Topaz O, Taylor AL. Interventricular septal rupture complicating acute myocardial infarction: From pathophysiologic features to the role of invasive and noninvasive diagnostic modalities in current management. *Am J Med*. 1992;93(6):683–8.
6. Yip HK, Fang CY, Tsai KT, Chang HW, Yeh KH, Fu M et al. The potential impact of primary percutaneous coronary intervention on ventricular septal rupture complicating acute myocardial infarction. *Chest*. 2004;125(5):1622–8.
7. Figueras J, Alcalde O, Barrabés JA, Serra V, Alguersuari J, Cortadellas J et al. Changes in hospital mortality rates in 425 patients with acute ST-elevation myocardial infarction and cardiac rupture over a 30-year period. *Circulation*. 2008;118(25):2783–9.
8. Ledakowicz-Polak A, Polak Ł, Zielińska M. Ventricular septal defect complicating acute myocardial infarction-still an unsolved problem in the invasive treatment era. *Cardiovasc Pathol*. 2011;20(2):93–8.
9. Menon V, Webb JG, Hillis LD, Sleeper LA, Abboud R, Dzavik V et al. Outcome and profile of ventricular septal rupture with cardiogenic shock after myocardial infarction: A report from the SHOCK Trial Registry. *J Am Coll Cardiol*. 2000;36(3 SUPPL. A):1110–6.
10. Lemery R, Smith HC, Giuliani ER, Gersh BJ. Prognosis in rupture of the ventricular septum after acute myocardial infarction and role of early surgical intervention. *Am J Cardiol*. 1992;70:147–151.
11. Thiele H, Kaulfersch C, Daehnert I, Schoenauer M, Eitel I, Borger M et al. Immediate primary transcatheter closure of postinfarction ventricular septal defects. *Eur Heart J*. 2009;30(1):81–8.
12. Calvert PA, Cockburn J, Wynne D, Ludman P, Rana BS, Northridge D et al. Percutaneous closure of postinfarction ventricular septal defect in-hospital outcomes and long-term follow-up of UK experience. *Circulation*. 2014;129(23):2395–402.
13. Florian S, De Waha S, Eitel I, Desch S, Fuernau G, Thiele H. Interventional post-myocardial infarction ventricular septal defect closure: A systematic review of current evidence. *EuroIntervention*. 2016;12(1):94–102.
14. Demkov M, Ruzyllo W, Kepka C, Chmielak Z, Konka M, Dzielinska Z. Primary transcatheter closure of postinfarction ventricular septal defects with the Amplatzer septal occluder- immediate results and up-to 5 years follow-up. *Eurointervention*. 2005;1(1):43-7.
15. Barker TA, Ramnarine IR, Woo EB, Grayson AD, Au J, Fabri BM et al. Repair of post-infarct ventricular septal defect with or without coronary artery bypass grafting in the northwest of England: A 5-year multi-institutional experience. *Eur J Cardiothoracic Surg*. 2003;24(6):940–6.
16. Arnaoutakis GJ, Zhao Y, George TJ, Sciortino CM, McCarthy PM, Conte J V.

- Surgical repair of ventricular septal defect after myocardial infarction: Outcomes from the society of thoracic surgeons national database. *Ann Thorac Surg.* 2012;94(2):436–44.
17. Yam N, Au TWK, Cheng LC. Post-infarction ventricular septal defect: Surgical outcomes in the last decade. *Asian Cardiovasc Thorac Ann.* 2013;21(5):539–45.
 18. Holzer R, Balzer D, Amin Z, Ruiz CE, Feinstein J, Bass J et al. Transcatheter Closure of Postinfarction Ventricular Septal Defects Using the New Amplatzer Muscular VSD Occluder: Results of a U.S. Registry. *Catheter Cardiovasc Interv.* 2004;61(2):196–201.
 19. Maltais S, Ibrahim R, Basmadjian AJ, Carrier M, Bouchard D, Cartier R et al. Postinfarction Ventricular Septal Defects: Towards a New Treatment Algorithm? *Ann Thorac Surg.* 2009;87(3):687–92.
 20. Deja MA, Szostek J, Widenka K, Szafron B, Spyt TJ, Hickey MSJ et al. Post infarction ventricular septal defect - Can we do better? *Eur J Cardio-thoracic Surg.* 2000;18(2):194–201.
 21. Moreyra AE, Huang MS, Wilson AC, Deng Y, Cosgrove NM, Kostis JB. Trends in incidence and mortality rates of ventricular septal rupture during acute myocardial infarction. *Am J Cardiol.* 2010;106(8):1095–100.
 22. Hirata N, Sakai K, Sakaki K, Ohtani M, Nakano S, Matsuda H. Assessment of perioperative predictive factors influencing survival in patients with postinfarction ventricular septal perforation. Classified by the site of myocardial infarction. *J Cardiovasc Surg (Torino).* 2000;41(4):547–52.
 23. Mantovani V, Mariscalco G, Leva C, Blanzola C, Sala A. Surgical repair of post-infarction ventricular septal defect: 19 Years of experience. *Int J Cardiol.* 2006;108(2):202–6.
 24. Coskun KO, Coskun ST, Popov AF, Hinz J, Schmitto JD, Bockhorst K et al. Experiences with surgical treatment of ventricle septal defect as a post infarction complication. *J Cardiothorac Surg.* 2009;6(4):3.
 25. Fishbein MC, Maclean D, Maroko PR. The histopathologic evolution of myocardial infarction. *Chest.* 1978;73(6):843–9.
 26. Tai S, Tang JJ, Tang L, Ni YQ, Guo Y, Hu XQ et al. Management and outcome of ventricular septal rupture complicating acute myocardial infarction: What is new in the era of percutaneous intervention? *Cardiol.* 2019;141(4):226–32.
 27. Neaton JD, Wentworth D. Serum cholesterol, blood pressure, cigarette smoking, and death from coronary heart disease. Overall findings and differences by age for 316,099 white men. Multiple Risk Factor Intervention Trial Research Group. *Arch Intern Med.* 1992;152(1):56–64.
 28. McEvoy JW, Blaha MJ, Defilippis AP, Lima JAC, Bluemke DA, Gregory Hundley W et al. Cigarette Smoking and Cardiovascular Events: Role of Inflammation and nfclinical Atherosclerosis from the Multiethnic Study of Atherosclerosis. *Arterioscler Thromb Vasc Biol.* 2015;35(3):700–9.

© 2021 Balasubramaniyan et al.; This is an Open Access article distributed under the terms of the Creative Commons Attribution License (<http://creativecommons.org/licenses/by/4.0>), which permits unrestricted use, distribution, and reproduction in any medium, provided the original work is properly cited.

Peer-review history:
The peer review history for this paper can be accessed here:
<https://www.sdiarticle4.com/review-history/72154>