



# Acute Hemifacial And Hemiparesis Caused By Hemorrhagic Vestibular Schwannoma; A Case Report

Jaber Hatam<sup>1</sup>, Mahisa Mokhtari<sup>1</sup>, Sayedali Ahmadi<sup>2</sup>, Eshagh Bahrami<sup>2</sup>, Marjan Mirsalehi<sup>3</sup>, Saleh Mohebbi<sup>3</sup>, Meysam Abolmaali<sup>4\*</sup>

<sup>1</sup>Rasoul Akram Hospital, Iran University of Medical Sciences, Tehran, Iran

<sup>2</sup>Department of Neurosurgery, Rasoul Akram Hospital, Iran University of Medical Sciences, Tehran, Iran

<sup>3</sup>ENT and Head & Neck Research Center and Department, Hazrat Rasoul Hospital, The Five Senses Health Institute, Iran University of Medical Sciences, Tehran, Iran

<sup>4</sup>Shefa Neuroscience Research Center, Khatam Alanbia Hospital, Tehran, Iran

## Abstract

Vestibular schwannoma is a benign and common slow-growing tumor that develops on the vestibular divisions of cranial nerve VIII. Some risk factors may enhance intratumoral hemorrhage risk which leads to tumor management to early surgical procedures. Hence, we describe a 57-year-old man presented with hearing loss and a 5\*8 mm vestibular schwannoma. Eight months later, the patient was referred with headache, nausea and vomiting, right hemifacial paresis, and hemiparesis. Magnetic resonance imaging (MRI) revealed a 45\*35 mm hemorrhagic vestibular schwannoma. Surgical pathology reported hemorrhagic vestibular schwannoma. This was a rare case of hemorrhagic vestibular schwannoma with none of the established risk factors for the intratumoral hemorrhage and presented with Wallenberg-like syndrome. Many risk factors can cause hemorrhagic vestibular schwannoma. We present one case of small vestibular schwannoma without any predisposing of hemorrhage and acute onset of same side hemifacial paresis and hemiparesis.

**Keywords:** Vestibular schwannoma; Acoustic neuroma; Intracranial hemorrhage; Hemorrhagic schwannoma

**Citation:** Hatam J, Mokhtari M, Ahmadi SA, Bahrami E, Mirsalehi M, Mohebbi S, et al. Acute hemifacial and hemiparesis caused by hemorrhagic vestibular schwannoma; A case report. Clin Neurosci J. 2022;9:e6. doi:10.34172/icnj.2022.06.

## \*Correspondence to

Meysam Abolmaali  
 Shefa Neuroscience Research  
 Center, Khatam Alanbia  
 Hospital, Tehran, Iran.  
 Email: dr.meysam.a@gmail.com  
 Tel: +9821-83553911

Published online January 24,  
 2022



## Introduction

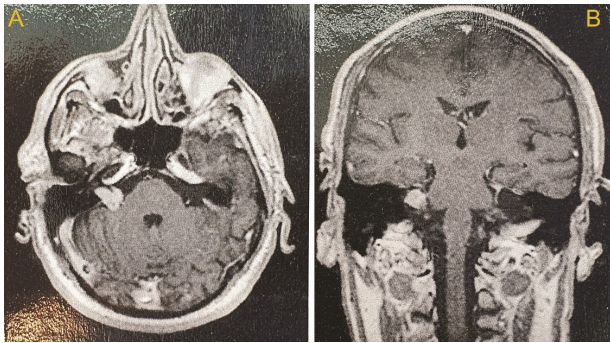
Acoustic neuromas, known as vestibular schwannomas (VS) originate from Schwann cells which produce the myelin sheath at the oligodendrocyte and Schwann cell junction (Obersteiner-Redlich zone) from the superior and inferior divisions of the 8<sup>th</sup> cranial nerve. These tumors slowly grow with an annual rate of 1-2 mm per year and account for approximately 8% of all intracranial tumors, and 80% of cerebellopontine angle (CPA) tumors.<sup>1</sup> Because of the compression of the vestibulocochlear nerve, the most common manifestations of this tumor are classified into tinnitus, vertigo, disequilibrium, and unilateral sensorineural hearing loss. Hemorrhage associated with VS is rare which was historically mentioned in less than 1% of cases. The rapid expansion of tumor due to intratumoral hemorrhage is associated with the acute onset of headache, nausea, vomiting, and facial nerve weakness.<sup>2</sup> We describe a patient with acute onset tinnitus, vertigo, disequilibrium, right hemiparesis, and right hemifacial paresis due to VS which was associated to intratumoral hemorrhage.

## Case Presentation

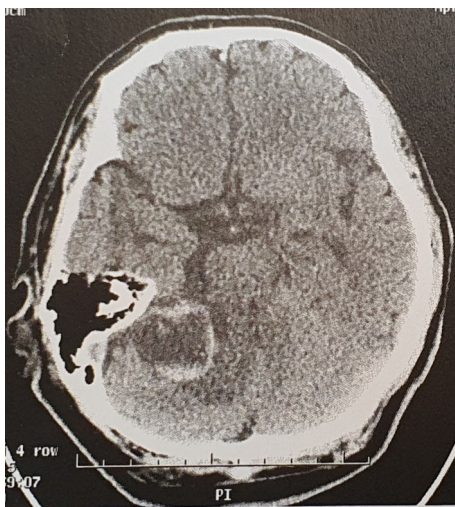
A 57-year-old man referred to the otorhinolaryngology clinic with the chief complaint of slowly progressive

hearing loss in his right ear a few months ago. He did not complain of tinnitus, vertigo, nausea, or vomiting. He did not mention any facial weakness or paresthesia or difficulty with swallowing. There was no significant point in the patient's family or past medical history. In the physical examination, the cranial nerves were intact. During his workup, a sensorineural hearing loss of the right ear was reported in the audiometry. Brain magnetic resonance imaging (MRI) indicated a 5\*8 mm intracanalicular mass lesion in the right internal auditory canal that seemed to be compatible with VS (Figure 1). Conservative treatment was performed for the patient, and he was scheduled for follow-up every 6 months.

Eight months later, the patient was referred to the emergency ward with acute onset of severe headache, nausea, vomiting, nystagmus, dysphagia, right side hemiparesis, and right side hemifacial paresis (grad III House-Brackman). Computed tomography (CT) showed a hemorrhagic mass in the right CPA with surrounding edema and local mass effect (Figure 2). MRI revealed a 45\*35 mm enhancing heterogenic, cystic mass in the right CPA which was most consistent with a hemorrhagic VS (Figure 3). The patient was scheduled for tumor resection surgery. During the surgery, the tumor was approached via a right retro-sigmoid craniotomy; some amounts of



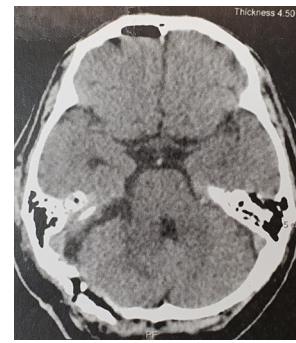**Figure 1.** (A and B) axial and Coronal T1 weighted with IV contrast MRI of the patient years ago, indicated a small right CPA tumor compatible with a vestibular schwannoma.



**Figure 2.** Spiral brain CT scan of the brain without IV contrast indicated a hemorrhagic mass in the right CPA with surrounding edema and mild local mass effect.

hematoma were evacuated from the tumor, and the entire tumor was resected. He was discharged on the 7<sup>th</sup> day after surgery. The histopathological report was compatible with hemorrhagic VS.

The patient has just unilateral sensory neural hearing loss, all other neurological deficits were recovered after two months of follow-up. CT scan showed no remnant



**Figure 4.** Follow-up, spiral brain CT scan of the brain without IV contrast showed no bleeding and mass.

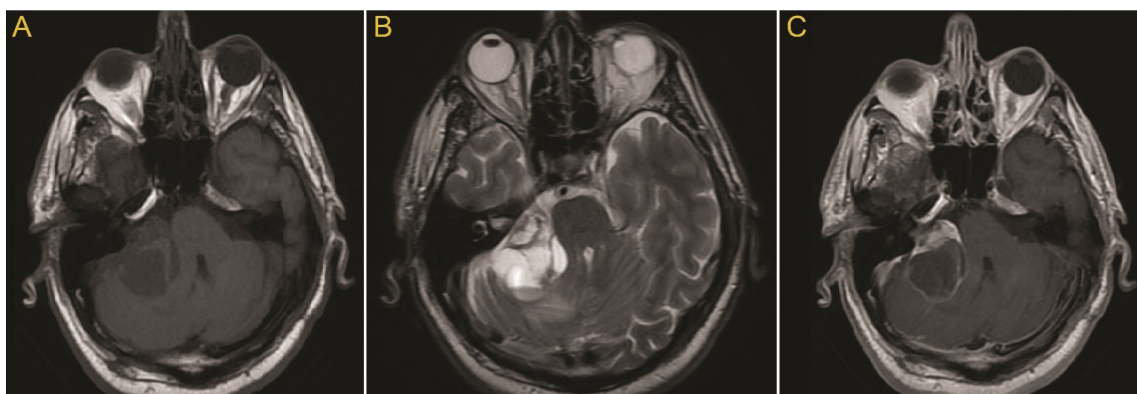
of tumor or hemorrhage at surgery site on two-month postoperative follow-up (Figure 4). Our patient gave his informed written consent to participate in the study.

### Discussion

VS originates from Schwann cells which produce the myelin sheath and arise from the superior and inferior vestibular segment of cranial nerve VIII. VS incidence is estimated to be 1.2 per 100 000 people per year, and this rate is expected to rise, partly because of the incidental diagnoses.<sup>3</sup> VS includes 8%–10% of primary intracranial tumors and 70–85% of CPA tumors.<sup>1</sup>

The intratumoral brain hemorrhage accounts for 11% of tumors, intratumoral hemorrhage in vestibular schwannoma is rare; also it was reported in less than 1% of all cases.<sup>1</sup> Less than 10% of VS complications are severe hemorrhage.<sup>4</sup> Intratumoral hemorrhage accounts for a 10% increase in mortality rate.<sup>5</sup> However, Carlson and colleagues showed no association between intratumoral hemorrhage and mortality growth.<sup>6</sup>

Although the exact etiology of intratumoral hemorrhage inside VS is unknown, in a literature review on all cases with histological report, vascular abnormalities such as dilated thin-walled vessels and hypervascularity were noted.<sup>1</sup> The large size of the tumor (> 2 cm) and rapid tumoral growth are two suggested etiologies for intratumoral hemorrhage, but rapid tumoral expansions can be the result of



**Figure 3.** (A, B) axial Magnetic T2 and axial magnetic T1 weighted without IV contrast resonance imaging. (C) axial Magnetic T1 weighted with IV contrast resonance imaging revealed a 4.5\*3.5 cm enhancing hemorrhagic cystic mass in the right CPA which was most consistent with a cystic hemorrhagic vestibular schwannoma.

intratumoral hemorrhage.<sup>7</sup> Using anticoagulants, cocaine, and trauma may lead to intratumoral hemorrhage, although, only a few cases were reported in this regard.<sup>8</sup> Moreover, factors such as tumor size, hypertension, and heavy physical exertion were mentioned as the known risk factors for the intratumoral hemorrhage in VS.<sup>6,9</sup> An association between hypertension control and the risk of intratumoral hemorrhage in patients with VS has been reported.<sup>9</sup>

Most VSs are treated with surgical resection or stereotactic radiosurgery. The venous congestion following the stereotactic surgery was suggested as a risk factor of intratumoral hemorrhage.<sup>10</sup> Although more studies are required to prove this relationship. Some articles reveal an association between intratumoral hemorrhage and cystic VS. Moreover, cystic VS potentially causes sudden neurological deterioration and deficit. It was seen that cystic VS presents itself with a sudden neurological deficit which can be irreversible with greater frequency than solid VS.<sup>11</sup> Because there is no difference between cystic and solid type, according to proliferation markers, it is suspected that this growth is caused by intratumoral hemorrhage rather than tumor proliferation.<sup>12</sup>

Based on the natural history of VS which grows at a rate from 1 to 2 mm per year, it is likely that the rapidly growing schwannomas are more prone to hemorrhage. If this theory is confirmed in the future by further research, rapid tumor growth can be considered a risk factor for intratumoral hemorrhage. The surgery will be indicated in these tumors because the intratumoral hemorrhage can cause neural deficit due to mass effect on the cranial nerves. For example, in cases with significant intratumoral hemorrhage, dysfunction of the 8<sup>th</sup> cranial nerve was seen in 46.9% of all cases.<sup>13</sup>

Further studies with larger sample size are needed to determine the exact association of intratumoral hemorrhage and the rate of mortality and morbidity. Better understanding of risk factors and closer follow-up may help the clinicians prevent unfavorable outcomes of intratumoral hemorrhage.

## Conclusion

Intratumoral hemorrhage in VS is a rare event. Based on previous literature, large size, cystic type, and history of radiosurgery are the predictors of hemorrhage in VS, but our case had none of these factors. Hence, some other factors could be involved as a risk factor of intratumoral hemorrhage in VS.

## Authors' Contribution

SA drafted, did background research and revised the manuscript. JH drafted, did background research, involved in the patient management, reviewed results, and revised the manuscript. MM drafted, did background research and involved in the patient management. MA drafted, reviewed results, and revised the manuscript. EB reviewed results and revised the manuscript. ZM involved in the patient management, drafted and did background research. MM involved in the patient management and reviewed

results. SM involved in the patient management and reviewed results.

## Conflict of Interest Disclosures

The authors declare no conflict of interest.

## Ethical Statement

Written informed consent was obtained from the patient for the publication of this report.

## References

1. Niknafs YS, Wang AC, Than KD, Etame AB, Thompson BG, Sullivan SE. Hemorrhagic vestibular schwannoma: review of the literature. *World Neurosurg.* 2014;82(5):751-6. doi: 10.1016/j.wneu.2013.02.069.
2. Carlson ML, Driscoll CL, Link MJ, Inwards CY, Neff BA, Beatty CW. A hemorrhagic vestibular schwannoma presenting with rapid neurologic decline: a case report. *Laryngoscope.* 2010;120 Suppl 4:S204. doi: 10.1002/lary.21671.
3. Sylvester MJ, Shastri DN, Patel VM, Raikundalia MD, Eloy JA, Baredes S, et al. Outcomes of vestibular schwannoma surgery among the elderly: analysis of the national inpatient sample. *Otolaryngol Head Neck Surg.* 2017;156(1):166-72. doi: 10.1177/0194599816677522.
4. Betka J, Zvěřina E, Balogová Z, Profant O, Skřivan J, Kraus J, et al. Complications of microsurgery of vestibular schwannoma. *Biomed Res Int.* 2014;2014:315952. doi: 10.1155/2014/315952.
5. Ganslandt O, Fahrig A, Strauss C. Hemorrhage into cystic vestibular schwannoma following stereotactic radiation therapy. *Zentralbl Neurochir.* 2008;69(4):204-6. doi: 10.1055/s-2008-1077074.
6. Carlson ML, Tombers NM, Driscoll CLW, Van Gompel JJ, Lane JJ, Raghunathan A, et al. Clinically significant intratumoral hemorrhage in patients with vestibular schwannoma. *Laryngoscope.* 2017;127(6):1420-6. doi: 10.1002/lary.26193.
7. Sughrue ME, Kaur R, Kane AJ, Rutkowski MJ, Yang I, Pitts LH, et al. Intratumoral hemorrhage and fibrosis in vestibular schwannoma: a possible mechanism for hearing loss. *J Neurosurg.* 2011;114(2):386-93. doi: 10.3171/2010.5.jns10256.
8. Sugihara S, Kinoshita T, Matsusue E, Fujii S, Ogawa T. Multicystic acoustic schwannoma with intratumoral hemorrhage: a report of two cases. *Magn Reson Med Sci.* 2004;3(2):101-4. doi: 10.2463/mrms.3.101.
9. Yang X, Liu J, Zhang Y, Richard SA. Tumor-associated hemorrhage in patients with vestibular schwannoma. *Acta Neurochir (Wien).* 2018;160(8):1563-9. doi: 10.1007/s00701-018-3588-7.
10. Murakami K, Jokura H, Kawagishi J, Watanabe M, Tominaga T. Development of intratumoral cyst or extratumoral arachnoid cyst in intracranial schwannomas following gamma knife radiosurgery. *Acta Neurochir (Wien).* 2011;153(6):1201-9. doi: 10.1007/s00701-011-0972-y.
11. Park CK, Kim DC, Park SH, Kim JE, Paek SH, Kim DG, et al. Microhemorrhage, a possible mechanism for cyst formation in vestibular schwannomas. *J Neurosurg.* 2006;105(4):576-80. doi: 10.3171/jns.2006.105.4.576.
12. Mathkour M, Helbig B, McCormack E, Amenta PS. Acute presentation of vestibular schwannoma secondary to intratumoral hemorrhage: a case report and literature review. *World Neurosurg.* 2019;129:157-63. doi: 10.1016/j.wneu.2019.05.075.
13. Castillo R, Watts C, Pulliam M. Sudden hemorrhage in an acoustic neuroma: case report. *J Neurosurg.* 1982;56(3):417-9. doi: 10.3171/jns.1982.56.3.0417.