



Naso-Pharynx Muco-Squamous Cell Carcinoma: About a Case

**A. Raihane^{1*}, Y. Oukessou¹, S. Rouadi¹, R. Abada¹, M. Roubal¹
and M. Mahtar¹**

¹ ENT Head and Neck Surgery Department, Ibn Rochd University Hospital, Faculty of Medicine and Pharmacy, Hassan II University, Casablanca, Morocco.

Authors' contributions

"This work was carried out in collaboration among all authors. Author MM designed the case. Author AR performed the observation, wrote the protocol and wrote the first draft of the manuscript. Authors MR and RA managed the analyses of the case. Author YO managed the literature searches and discussion. All authors read and approved the final manuscript."

Article Information

Editor(s):

(1) Dr. Prabakaran Nagarajan, The Ohio State University, USA.

Reviewers:

(1) Selcuk Seber, Tekirdag Namik Kemal University, Turkey.

(2) Driele Tavares, Federal University of São Carlos, Brazil.

Complete Peer review History: <http://www.sdiarticle4.com/review-history/67039>

Case Study

Received 28 January 2021

Accepted 05 April 2021

Published 11 April 2021

ABSTRACT

Muco-squamous cell carcinoma is a rarely localized tumour in the cavum. Its therapeutic characteristics and prognostic factors remain unclear given the limited number of cases reported in the literature. The purpose of our work is to study the clinical, therapeutic and prognostic particularities of this entity.

We report the case of a patient aged 59 years, who consulted for a symptomatology made of headache, epistaxis, decrease of the visual acuity of the right eye with association of otological signs. Nasal endoscopy revealed budding formation of the cavum roof and cervical examination did not objectify lymphadenopathy. The scanner imaging showed a tissue process of the roof and posterior wall of the cavum measuring 58 mm 59 mm 47 mm, with extension to the infra temporal pit and invasion of the skull base. The biopsy of the cavum concluded to muco-squamous cell carcinoma. After extension assessment, the tumor was classified T4BN2M0. The patient was treated with exclusive radiotherapy with no local progression or remote metastases after 12 months of regression.

*Corresponding author: E-mail: adil.raihane720@gmail.com;

Keywords: Nasopharynx; malignant tumour; muco-squamous cell carcinoma.

1. INTRODUCTION

Muco-squamous cell carcinoma is a malignant tumour frequently found in the main salivary glands and accessories of the oral cavity. It can exceptionally reach the nasal cavities, sinuses or cavum [1]. Muco-squamous cell carcinoma of the naso-pharynx is a rare entity. Its clinical, therapeutic and prognostic characteristics remain unclear given the limited number of cases described in the literature. We report a case of muco-squamous cell carcinoma of cavum through which we will discuss the clinical features, the therapeutic possibilities as well as the prognostic factors of this entity.

2. CASE PRESENTATION

This is a 59 year old patient with a medical history of type 2 diabetes treated by oral anti diabetes and high blood pressure, admitted to our department for a symptomatology that has been evolving for 3 months with headache, epistaxis, unilateral nasal obstruction complicated to bilateral nasal obstruction and decreased visual acuity of the right eye, with notion of otological signs made of right tinnitus,

hypoacusia and sensation of buzzing of the right ear. Nasal endoscopy revealed budding formation of the cavum roof and posterior wall and clinical examination objectified a slight right exophthalmia with decreased visual acuity and paralysis of the sixth homolateral cranial pair without cervical lymphadenopathy nor other detectable lesions. Scanner imaging showed a tissue process of the roof and posterior wall of the cavum measuring 58 mm 59 mm 47 mm, with extension to the right parapharyngeal fat, the pre-stylian space, the medial and lateral pterygoid muscles with lysis of the pterygoid process, the occiput basi with intra-cranial extension and backward to the pharyngeal and pre-vertebral space without bone lysis at this level (Fig. 1).

Magnetic reasoning imaging showed a locally advanced naso pharyngeal process with invasion at the top of the clivus and body of the sphenoid and filling of the foramen ovale and lacerum with intra-cranial extension involving the right cavernous sinus and meningeal envelopes of the temporal lobe and posterior cerebral fossa. Retro-pharyngeal lymphadenopathy and lia and V territories were objectified Fig. 2.

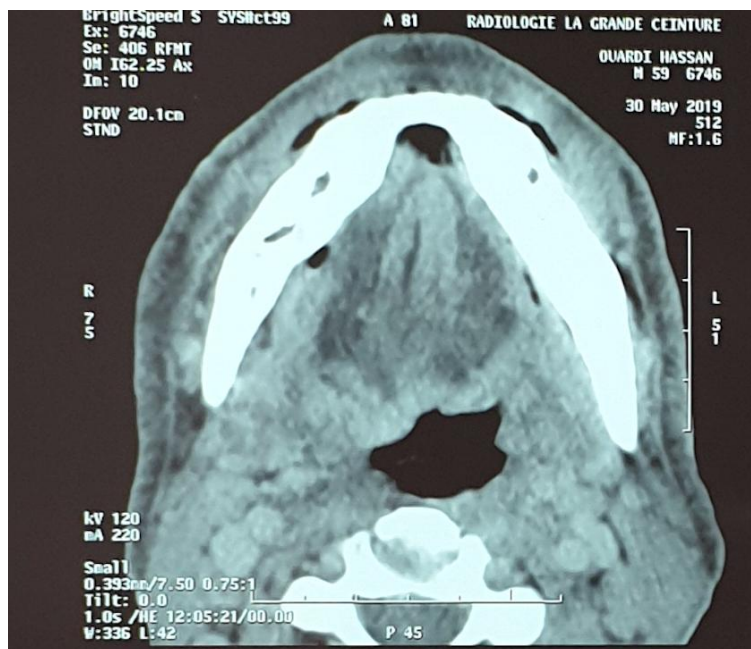

Fig. 1. Axial section of scan of the nasopharynx with injection of contrast showing a bulky process of the posterior and upper wall of the nasopharynx, taking contrast in a heterogeneous way

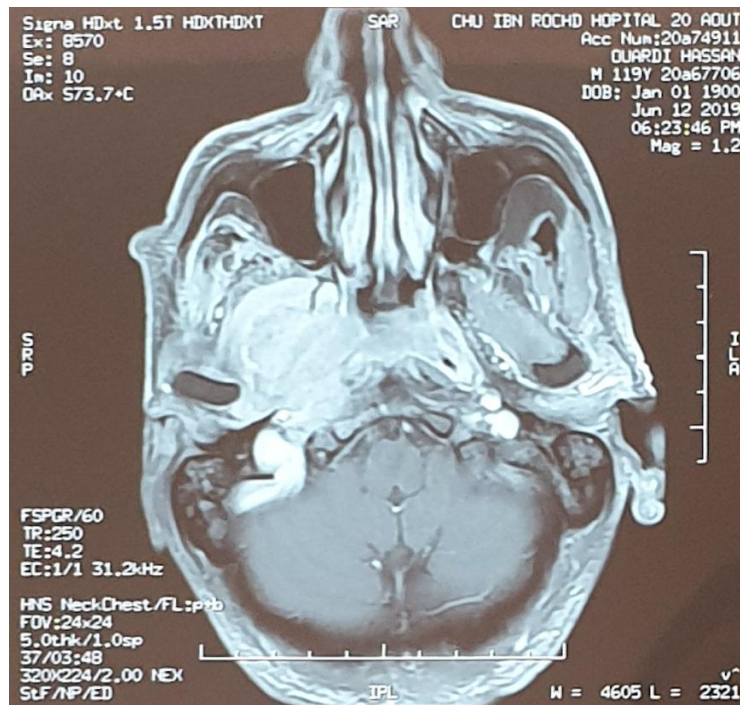


Fig. 2. Axial section of an injected magnetic resonance imaging showing a process of nasopharynx invading the clivus, right cavernous sinus and meninges of the right temporal lobe and posterior cerebral fossa

The biopsy concluded that there was a grade of malignancy in arm muco-squamous cell carcinoma.

After extension assessment based on a chest-abdominal-pelvic computed tomography, the tumor was classified T4BN2M0. The patient was treated with exclusive radiotherapy at a dose of (65Gy). Monitoring did not target local progression or remote metastasis after an 12 months decline.

3. DISCUSSION

Muco-squamous cell carcinoma was first described in 1945 by Stewart as a malignant tumour of the main salivary glands and accessories [2]. It represents the carcinoma that most affects the parotid gland [1]. Nasopharynx disease accounts for 2% of all malignant tumors in the accessory salivary glands, while oral cavity and oropharynx are found in 70.1% of cases [3]. Given its extreme rarity, very few articles have been published on this subject. Only forty-four cases were listed in nine studies of Anglo-Saxon literature [3]. There is a slight female predominance. The average age of discovery varies between 40 and 60 according to the

authors. Occurrence in young children and adolescents remains rare [1,4]. Like any cancer, functional signs depend on localization, the degree of infiltration of neighborhood structures and remote metastases. The most common calling signs are nasal obstruction, epistaxis and hypoacusis [4]. No damage to the cranial nerves was objectified in the series studied by Xu [3]. In the Zhang study, ten of the 13 cases studied were stage I and stage II, suggesting that muco-squamous cell carcinoma of cavum, like other salivary gland-like tumours, is generally found in early stages [4]. The behaviour of this histological type is different from that of squamous cell carcinomas in naso-pharyngeal involvement [1]. The incidence of lymph node damage and remote metastases in naso-pharyngeal sites of salivary gland-like tumours, in particular muco-squamous cell carcinoma, is less than 20-25% according to some authors [1,3]. Surgery and radiotherapy (or concomitant radiation chemotherapy) are the most discussed treatment options but attitudes remain controversial depending on the series.

Ellis described his experience with radiotherapy in the treatment of malignant tumors of the accessory salivary glands. Of the 52 cases

reported, early stage tumours were controlled by both radiotherapy and surgery/radiotherapy [5]. Efficacy of exclusive radiotherapy treatment has been found in several cases of muco-squamous cell carcinoma of the larynx [4]. However, Hosokawa found no significant difference in the local control of death between surgery alone and the combination of surgery and radiotherapy [6].

Given the limited data available, the limited number of cases studied, usually in series containing in addition to muco-squamous cell carcinoma, other cancers of the salivary gland type, it is still early to conclude as to the radio-sensitivity of this tumour. Schramm and Imola recommend as a treatment of salivary gland naso-pharyngeal tumours, a first surgery, with tumor resection with obviously lymph node, followed by adjuvant radiotherapy [7]. For Zhang, first radiotherapy was performed in 8 patients with muco-squamous cell carcinoma of the nasopharynx, a stabilization of the tumor was obtained in all cases with a single case of complete remission. Eleven patients were operated, a transmaxillary tumor resection was performed in 10 cases (1 case of rhinotomy) with lymph node evident in cases of suspected lymphadenopathy clinically and ultrasound. Of the eleven patients operated (primary or remedial surgery), 4 had macroscopic resection limits invaded. The latter had adjuvant radiotherapy, and evolution was marked by the absence of local progression or distant metastases. This suggests a likely role of post-operative radiotherapy in improving life expectancy [7]. According to Cao, the optimal treatment of naso-pharyngeal tumors of the salivary gland type is the combination of surgery/radiotherapy [8].

Technological advances in radiotherapy have allowed significant irradiation of the tumour bed without affecting nearby organs. High doses were correlated with better results for tumours from different localizations. Radio-chemotherapy is indicated in locally advanced cancers of the head, neck and cavum [1]. Chemotherapy alone is primarily indicated for metastatic or recurrent tumours and has not proven to be particularly effective in the treatment of muco-squamous cell carcinoma.

Based on literature data, age over 40, fixed tumours, advanced stages, ganglion metastases and high histological grade are important prognostic factors of muco-squamous cell carcinoma of the head and neck with an estimated overall survival rate of 67.2% in the

recent Granic study [9,10]. In a series of 8 patients with muco-squamous cell carcinoma cavum, the overall 5 years survival rate was 56.3% and the disease free survival rate was 18.8% [3].

4. CONCLUSION

Muco-squamous cell carcinoma, frequently found in the main salivary glands, rarely affects the nasopharynx. The optimal treatment would be primary surgery for non-resectable tumours, not metastasized regardless of histological grade, followed by post-operative radiotherapy in case of invaded surgical boundaries, high grade tumour or macroscopic tumour residue. In other cases, radiation chemotherapy finds its indication. Given the rarity of the pathology and the limited number of cases reported in the literature, multicentric prospective studies would be necessary for a better codification of treatment and a more objective analysis of prognostic factors.

CONSENT AND ETHICAL APPROVAL

As per university standard guideline, participant consent and ethical approval have been collected and preserved by the authors

COMPETING INTERESTS

Authors have declared that no competing interests exist.

REFERENCES

1. Ollero JM, Morón AH, Luis AM, Sánchez SM, Nazarewsky AA, López MJ, et al. Nasopharyngeal mucoepidermoid carcinoma: A case report and review of literature. *Rep Pract Oncol radiother.* 2012;18(2):117–20.
2. Stewart FW, Foote FW, Becker WF. Mucoepidermoid tumors of salivary glands. *Ann Surg.* 1945;122(5):820–44.
3. Xu X, Chao SS, Ong YK. Endoscopic Endonasal Resection of Re-current Nasopharyngeal Mucoepidermoid Carcinoma. *J Craniofac Surg.* 2016;27(4): 1053-5
4. Zhang XM, Cao JZ, Luo JW, Xu GZ, Gao L, Liu SY et al. Nasopharyngeal mucoepidermoid carcinoma: A review of 13 cases. *Oral Oncol.* 2010;46(8):618–21.
5. Ellis ER, Million RR, Mendenhall WM, Parsons JT, Cassisi NJ. The use of

- radiation therapy in the management of minor salivary gland tumors. *Int J Radiat Oncol Biol Phys.* 1988;15(3):613–7.
6. Hosokawa Y, Shirato H, Kagei K, Hashimoto S, Nishioka T, Tei K et al. Role of radiotherapy for mucoepidermoid carcinoma of salivary gland. *Oral Oncol.* 1999;35(1):105-11.
 7. Schramm VL Jr, Imola MJ. Management of nasopharyngeal salivary gland malignancy. *Laryngoscope.* 2001;111(9):1533-44.
 8. Cao CN, Zhang XM, Luo JW, Xu GZ, Gao L, Li SY et al. Primary salivary gland-type carcinomas of the nasopharynx: Prognostic factors and outcome. *Int. J. Oral Maxillofac. Surg.* 2012;41:958–64
 9. Pires FR, de Almeida OP, de Araújo VC, Kowalski LP. Prognostic factors in head and neck mucoepidermoid carcinoma. *Arch Otolaryngol Head Neck Surg.* 2004; 130(2):174-80.
 10. Granic M, Suton P, Mueller D, Cvrljevic I, Luksic I. Prognostic factors in head and neck mucoepidermoid carcinoma: experience at a single institution based on 64 consecutive patients over a 28-year period. *Int J Oral Maxillofac Surg.* 2018; 47(3):283-8.

© 2021 Raihane et al.; This is an Open Access article distributed under the terms of the Creative Commons Attribution License (<http://creativecommons.org/licenses/by/4.0>), which permits unrestricted use, distribution, and reproduction in any medium, provided the original work is properly cited.

Peer-review history:
The peer review history for this paper can be accessed here:
<http://www.sdiarticle4.com/review-history/67039>